

A model system for polydactyly; The Korean Ogye

Eun-Jung Kim^{1*}, Jae-Woo Kim², David William Green¹, Han-Sung Jung^{1*}

¹Division in Anatomy and Developmental Biology, Department of Oral Biology, Oral Science Research Center, Yonsei University College of Dentistry, Seoul, Korea, ²Plymouth University Peninsula School of Medicine, Plymouth, United Kingdom

접수: 2015년 11월 18일 / 수정접수: 2015년 12월 8일 / 게재 승인: 2015년 12월 9일 / 출간: 2015년 12월 31일

Keywords: Korean Ogye, digit, polydactyly, polyphalange, *Shh*

INTRODUCTION

Polydactyly, the addition of one or more extra digits, occurs in various vertebrates as well as in humans with prevalence ranging from 5 to 19 per 10,000 live births^{1,2}. This common malformation has a genetic cause and was one of the earliest genetic mutations studied in chicken³. Furthermore, polydactyly relates to the phenotype found in many domestic chicken breeds including Dorking, Silkie, and Sultan. Autosomal inheritance is shown in polydactyly of chicken with incomplete penetrance⁴. One proposal is that it is

controlled by more than one gene⁵.

Sonic hedgehog (*Shh*) is a principal master regulator determining the digit number and identity in the vertebrate limbs. *Shh* is expressed in posterior region of mesenchyme, known as the zone of polarizing activity (ZPA) in the limb bud. *Shh* is a key morphogen at the anterior-posterior limb axis in early embryogenesis^{6,7}. Intrinsic regions of *Lmbr1* (a ZPA regulatory sequence, ZRS), which is located 1Mb upstream of *Shh*, regulate *Shh* expression in the ZPA. Mutations in intron3 of *LMBR1* are associated with ectopic *Shh* expression in the limb and / or polydactyly in chickens⁷⁻¹⁰. Along with this, deletion of intron 5 of *LMBR1* (1654 bp) causes oligozeugodactyly (loss of posterior element of zeugopod along with all digits except digit1 in the leg) for Silkie¹¹. The Silkie has polydactylous

* Corresponding author: Han-Sung Jung and Eun-Jung Kim

Department of Oral Biology, Yonsei University College of Dentistry, 50 Yonsei-ro, Seodaemun-Gu, Seoul, Korea.
Tel: +82-2-2228-3065, Fax: +82-2-312-8012
E-mail: hsjung@yuhs.ac and blueleah@yuhs.ac

feet and expresses ectopic *Shh* as well as the expression of genes downstream of Shh signaling, *Hoxd13* and *Bmp2*, in the anterior leg bud from stage 25 Hamburger and Hamilton (HH) stages¹².

Korean Ogye, which has been mis-named as Korean Native Ogol chickens, is a species protected by the Korean government (Protected Species Act No. 265), and has been studied at genetic and population levels¹³⁻¹⁵. Korean Ogye has black feathers, as well as black bones, skin, eye, and claws. It has been known that purebred of Korean Ogye has four toes with no fine furs, whereas mixed Korean Ogye expresses polydactyly with 5-6 toes with fine furs. This study aims to reveal the phenotype and genetic expressions related to Korean Ogye polydactyly.

MATERIALS AND METHODS

Animals

The Korean Ogye eggs were purchased from Cheonanogolgye farm and incubated at Yonsei University. Fertilized eggs were incubated under 75% humidity at 37°C for 4 days, 5 days, and 10 days. Collected samples were rinsed in phosphate buffered saline (PBS), and fixed with 4% paraformaldehyde (PFA). Embryos were staged according to Hamburger and

Hamilton (HH) stages.

Skeletal staining

Embryos were fixed at days 10 of incubation in 95% ethanol and stained for bone and cartilage using 0.1% alizarin red and 0.3% alcian blue using in 1% acetic acid, dehydrated in ethanol, and cleared in potassium hydroxide.

In situ hybridization

Tissues were fixed overnight in 4% PFA. Hybridizations were performed on Korean Ogye embryos with digoxigenin-labelled cRNA probes in hybridization buffer for 18 hours at 72°C. Hybridization signals were detected by alkaline-phosphatase-conjugated anti-digoxigenin antibodies with nitro blue tetrazolium chloride/5-bromo-4-chloro-3-indolyl phosphate and toluidine salt substrate (Roche, Mannheim, Germany).

RESULT AND DISCUSSION

Korean Ogye has polydactylous feet. Korean Ogye is an ancient chicken breed that originated from South East Asia, and introduced to Korea in the 1300s. Mixed Korean Ogye has polydactylous feet with 5-6 digits (Fig. 1B). The polydactyly of Korean Ogye produce variations, from an extra phalanx in digit 1 (Fig.

1D - 1E) to 2 extra anterior digits (data not shown). Genetic studies have shown that Silkie's polydactylous feet follows autosomal-dominant patterns with identical variations existing within mixed Korean Ogye polydactyly. However, the presence of 5 toes on each foot is the breeding standard for Silkie. The extra phalanx of digit 1 in Silkie occurs in the region of the metacarpus¹⁶⁾. Furthermore, Korean Ogye has another variation with an extraphalanx in digit 1, which occurs in the proximal phalanx (Fig. 1E). Polyphalange, in which the number of toes is

normal but the most anterior toe has an extraphalanx, has been well known as a common outcome of matings between polydactylous birds, and is considered as a variation of polydactyly¹⁶⁾. Therefore, the preaxial polyphalange could be a common formation between the mixed Korean Ogye, but not the pure breed Korean Ogye.

The ectopic *Shh* was expressed in Korean Ogye leg

Mutations within the ZRS have been reported to induce ectopic anterior *Shh* expression in the developing mouse limb, as well as the Silkie leg^{7,8,12)}. To identify the ectopic *Shh* expression in Korean Ogye, we performed whole-mount *in situ* hybridization of Korean Ogye embryos from HH 24 to HH 27. In Korean Ogye, normal posterior *Shh* expression in ZPA was observed from HH 24 to HH 26 (Fig. 2A-C). As consistent with previous report of Silkie, the posterior *Shh* domain in Korean Ogye is slightly larger, and is expressed for longer as compared to wild type legs¹⁶⁾. Interestingly, unlike Silkie, the ectopic *Shh* expression in the anterior region of Korean Ogye embryos was not detected from HH 24 to HH 26. The anterior ectopic *Shh* was expressed at HH 27, not HH 25, which was slightly late compared to Silkie (Fig. 2D).

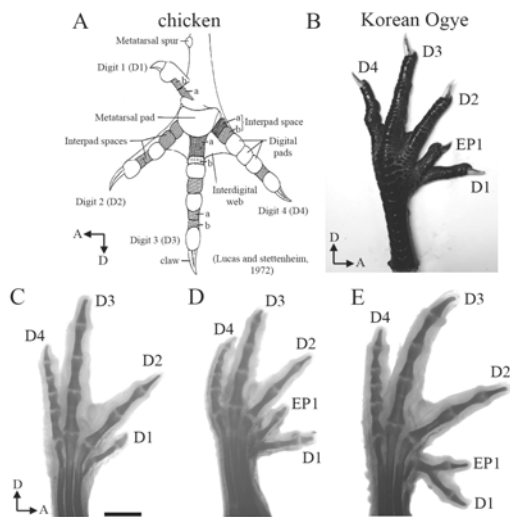


Figure 1. The morphology of Korean Ogye foot polydactyly. (A) the structure of the chicken foot. (B) Korean Ogye foot with the polydactylous phenotype. (C) 4 digits in pure bred Korean Ogye, identified from anterior to posterior (D1, D2, D3, D4). (D), (E) Korean Ogye foot with 5 digits (D1, ED1, D2, D3, D4). (D) and (E) are different variation of polyphalange. (D: digit, EP: extra phalanx in digit 1, A: anterior, D: distal part of limb). Scale bar = 250µm

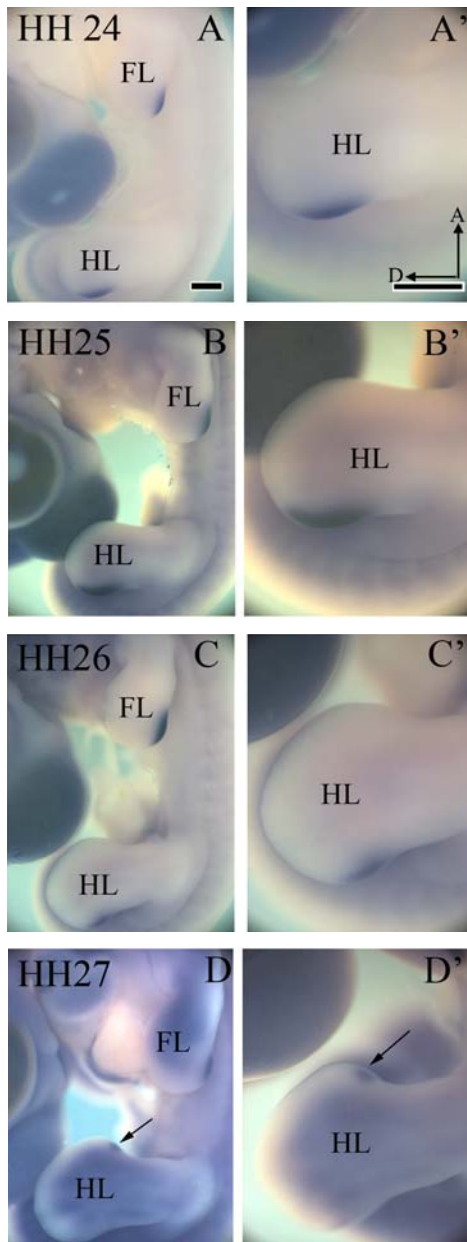


Figure 2. Expression of *Shh* during development of the Korean Ogye leg. (A), (A') Hamburger and Hamilton stage (HH) 24. (B) and (B') HH 25. (C) and (C') HH 26. (D) and (D') HH 27; *Shh* expression in anterior and posterior. (Arrow: the ectopic *Shh* expression, FL: forelimb, HL: hindlimb, A: anterior, D: distal part of limb, A', B', C' and D': higher magnification). Scale bars = 500 μ m

In Silkie, the increased range of *Shh* signaling has been suggested to extra anterior digit 1¹⁶). Furthermore, in polydactylous Dorking chicken, a similar model of the ectopic *Shh* expression has been proposed for the initiation of preaxial polydactyly¹⁷). They suggested that an anterior ectopic expression of *Shh* in addition to ectopic *Fgfs* in the AER, an extra digit 2 forms in Dorking hindlimbs. In this study, the consequence of late ectopic *Shh* expression in the anterior part of leg at HH 27 led to an extra-phalanx in the proximal phalanx, rather than the metacarpal phalanx. Therefore, the preaxial polydactyly of the Korean Ogye shows a different variation compared to Silkie and Dorking chicken. Further studies in Korean Ogye are needed to examine the genetic relationship between ectopic *Shh* expression and the Fgf signaling. Moreover, genome wide mapping of the Korean Ogye would be needed for further studies in this regard.

REFERENCES

1. Sesgin MZ, Stark RB: The incidence of congenital defects. *Plast Reconstr Surg* 27: 261-267, 1961.
2. Zguricas J, Heus H, Morales-Peralta E, Breedveld G, Kuyt B, Mumcu EF, Bakker W, Akarsu N, Kay SP, Hovius SE: Clinical and genetic studies on 12 preaxialpolydactyly families and refinement of the localisation of the gene responsible to a 1.9 cM region on chromosome 7q36. *J Med Genet* 36:33-40, 1999.

3. Punnett RC, Pease MS: Notes on polydactyly. *J Genet* 21:341-366, 1929.
4. Somes R: Mutations and major variants of muscles and skeleton in chickens R. Crawford (Ed.). *Poultry Breeding and Genetics*. 209-237, 1990.
5. Dorshorst B, Okimoto, RC: Ashwell Genomic regions associated with dermal hyperpigmentation, polydactyly and other morphological traits in the Silkie chicken. *J Hered* 101: 339-350, 2010.
6. Lettice LA, Horikoshi T, Heaney SJ, van Baren MJ, van der Linde HC, Breedveld GJ, Joosse M, Akarsu N, Oostra BA, Endo N, Shibata M, Suzuki M, Takahashi E, Shinka T, Nakahori Y, Ayusawa D, Nakabayashi K, Scherer SW, Heutink P, Hill RE, Noji S: Disruption of a long-range cis-acting regulator for Shh causes preaxial polydactyly. *Proc Natl Acad Sci* 28:99(11):7548-7553, 2002.
7. Lettice LA, Hill AE, Devenney PS, Hill RE: Point mutations in a distant sonic hedgehog cis-regulator generate a variable regulatory output responsible for preaxial polydactyly. *Hum Mol Genet* 17:978-985, 2008.
8. Hill RE, Heaney SJ, Lettice LA: Sonic hedgehog: restricted expression and limb dysmorphologies. *J Anat* 202:13-20, 2003.
9. Masuya H, Sezutsu H, Sakuraba Y, Sagai T, Hosoya M, Kaneda H, Miura I, Kobayashi K, Sumiyama K, Shimizu A, Nagano J, Yokoyama H, Kaneko S, Sakurai N, Okagaki Y, Noda T, Wakana S, Gondo Y, Shiroishi T: A series of ENU-induced single-base substitutions in a long-range cis-element altering Sonic hedgehog expression in the developing mouse limb bud. *Genomics* 89:207-224, 2007
10. Wang ZQ, Tian SH, Shi YZ, Zhou PT, Wang ZY, Shu RZ, Hu L, Kong X: A single C to T transition in intron 5 of LMBR1 gene is associated with triphalangeal thumb-polysyndactyly syndrome in a Chinese family. *Biochem-Biophys Res Commun* 355:312-317, 2007.
11. Maas SA, Suzuki T, Fallon JF: Identification of spontaneous mutations within the longrange limb-specific sonic hedgehog enhancer (ZRS) that alter sonic hedgehog expression in the chicken limb mutants oligozeugodactyly and Silkie breed. *Dev Dyn* 240: 1212-1222, 2011
12. Arisawa K, Yazawa S, Atsumi Y, Kagami H, Ono T: Skeletal analysis and characterisation of gene expression related to pattern formation in developing limbs of the Japanese Silkie fowl. *Poult Sci* 43:126-134, 2006.
13. Han SW, Oh BK, and Kim SH: Studies on the hereditary characters and some economical traits of Korea Native Ogol fowl: II. Fertility, hatchability, egg production and body weight. *Korean J Poult Sci* 13:179-186, 1986 (in Korean)
14. Lee SJ, Hwang KC, Choi KD, Lee HK, Shin YS, Han JY: Genetic analysis of Korean Native Ogol Chickens with DNA fingerprinting. *Korean J Anim Science* 37:207- 215, 1995. (in Korean)
15. Seo DS, Hong YH, Choi KD, Yang MH, Shin YS, Han JY: Production of chimeric chickens (White Leghorn-Korean Native Ogol) by blastodermal cell transfer. *Korean J Anim Science* 37:27-32, 1995. (In Korean)
16. Dunn IC, Paton IR, Clelland AK, Sebastian S, Johnson EJ, Mcteir L, Windsor D, Sherman A, Sang J, Burt DW, Tickle C, Davey MG: The chicken polydactyly (Po) locus causes allelic imbalance and ectopic expression of Shh during limb development. *Dev Dyn* 240(5):1163-1172, 2011.
17. Bouldin CM, Harfe BD: Aberrant FGF signaling, independent of ectopic hedgehog signaling, initiates preaxial polydactyly in Dorking chickens. *Dev Biol* 334:133-141, 2009
18. Lucas AM and Stettenheim PR: *Avian Anatomy Integument Part I*. US Government Printing Office P 69, 1972.

ACKNOWLEDGEMENT

This work was supported under the frame-work of international cooperation program managed by National Research Foundation of Korea (No.201.3K2A2A4003305).

국문초록

다지증 연구를 위한 새로운 모델 시스템: 한국 오계

김은정^{1*}, 김재우², 윌리엄 데이비드 그린¹, 정한성^{1*}

¹*Division in Anatomy and Developmental Biology, Department of Oral Biology, Oral Science Research Center, Yonsei University College of Dentistry, Seoul, Korea,*

²*Plymouth University Peninsula School of Medicine, Plymouth, United Kingdom*

손가락 혹은 발가락이 추가적으로 발생하는 다지증은 많이 생기는 사지 기형 중 하나이다. Korean Ogye (Korean Native Ogol chickens)은 고품질의 닭고기를 얻기 위해 1300년대 이후로 한국에서 길러오고 있는 닭의 종류이다. 잡종 Korean Ogye 는 전축 다지증을 가지고 있어 다지증 연구에 좋은 모델시스템이 된다.

본 연구에서는, Korean Ogye의 다리를 골염색을 이용하여 다지증의 여러 형태를 분석하였다. 많은 이전 연구에서 사지끝의 앞쪽 부분에 Shh의 이소성 발현으로 인하여 다지증이 발생된다고 보고 되어지고 있다. 본 연구에서 Shh을 in situ hybridization 방법을 통하여 그 발현 양상을 본 결과, HH24에서 HH26 시기까지는 뒤쪽 부분에 나오고, HH27 시기에는 앞쪽 부위에 Shh의 이소성 발현이 나타남을 확인하였다. 그러므로, 본 연구로 다지증에 Shh 의 발현이 중요함을 확인하였으며, 이는 척추동물 다지증의 여러 형태에 관여하는 분자생물학 연구에 기본이 될 것이다.

주제어 : 한국 오계, 손(발)가락, 다지증, 손마디과다증, *Shh*