

5 : C (house) 77

가 16 , 가
5 2 가
16 ,
5 가
가 9 (82%), 2 (18%)

1992 1 1999 12

가 11 C
가 C
1 C 62
6 (house) (house) 38
6 (Table 1).

7)
C
10 (house)
6 (Table 2).

1)
C
(house) 11 가 7 ,
가 4 , 40 60 가 7 (64%)

2)
11 9 (82%)
가 6 (55%), 5
(46%), 5 (46%)

3)
11
10 (91%)
1 (9%)

4)
11
1 20
1 5 1 (9%), 6 10 가 6 (55%)
가 11 15 2 (18%), 20
2 (18%) 1 50
가

5)
2

Table 1. Operation time

| Operation time | No of cases | |
|----------------|----------------|-------------------------------|
| | C-anoplasty | House shaped advancement flap |
| Within 30 mins | — | — |
| 30 60 mins | 3 | 5 |
| 60 90 mins | 2 | 1 |
| Over 90 mins | 1 | — |
| Total | 6 | 6 |
| Mean | 62 mins | 38 mins |

Table 2. Duration of hospitalization

| Duration of hospitalization | No of cases | |
|-----------------------------|----------------|-------------------------------|
| | C-anoplasty | House shaped advancement flap |
| 1 5 days | — | 2 |
| 5 10 days | 4 | 4 |
| 10 15 days | 1 | — |
| Over 15 days | 1 | — |
| Total | 6 | 6 |
| Mean duration | 10 days | 6 days |

8)

C
 6 8 가 4 (67%), (house)
 3 5 가 5 (83%)
 C 46
 (house)
 28 (Table 3).

9)

가 C
 1 가 4 (67%), 2
 2 (33%) (house)
 2 4 (67%), 3 2 (33%)
 (Table 4).

10)

(1) C⁵⁻⁷: C

‘C’

C

(Fig. 1a).

C

4 가

C

(2.1) C
 (2.1') 가
 (Fig. 1b).

2-0

()

C

, 1 1'

C

2-0

4-0

(Fig. 1c).

Table 3. Duration of wound healing

| Duration of wound healing | No of cases (%) | |
|---------------------------|-----------------|-------------------------------|
| | C-anoplasty | House shaped advancement flap |
| 3 5 wks | 2 (33%) | 5 (83%) |
| 6 8 wks | 4 (67%) | 1 (17%) |
| Total | 6 (100%) | 6 (100%) |
| Mean | 46 days | 28 days |

Table 4. Number of flap direction at the same operation

| Number of flap site | No of cases (%) | |
|---------------------|-----------------|-------------------------------|
| | C-anoplasty | House shaped advancement flap |
| One | 4 (67%) | |
| Two | 2 (33%) | 4 (67%) |
| Three | | 2 (33%) |
| Total | 6 (100%) | 6 (100%) |

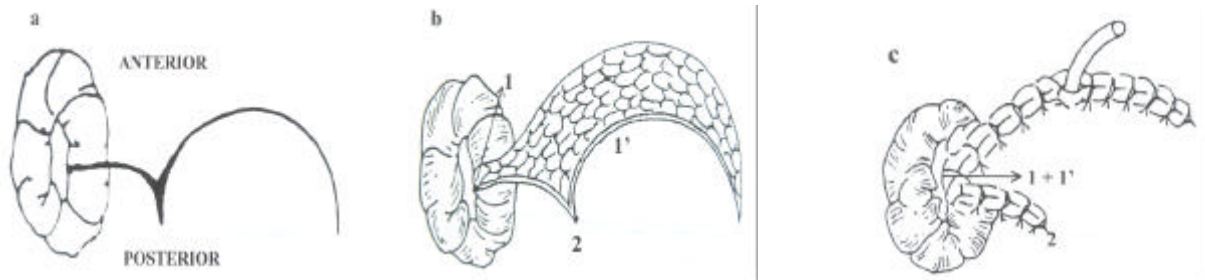


Fig. 1. C-anoplasty⁵ Incision the anal skin from dentate line to anal verge through full-thickness skin (a). The distance from one corner of the C-incision to the proximal end of the anal radial incision at the dentate line (2,1) is measured, and an equal distance to the C-flap (2,1') is marked (b). Cover the anal defect with the C-flap as it is drawn into the dentate line (1,1').

(2) (house)
(house)

8 :

. Christensen

Christensen 15

가

(Fig. 2a A B)

3-0

Y

(Fig. 2a).

(Fig. 2c).

11)

(Fig. 2b).

Christensen

C

6 1 (17%)

1 (17%)

가

가 2

(house)

(house)

6

(Table 5).

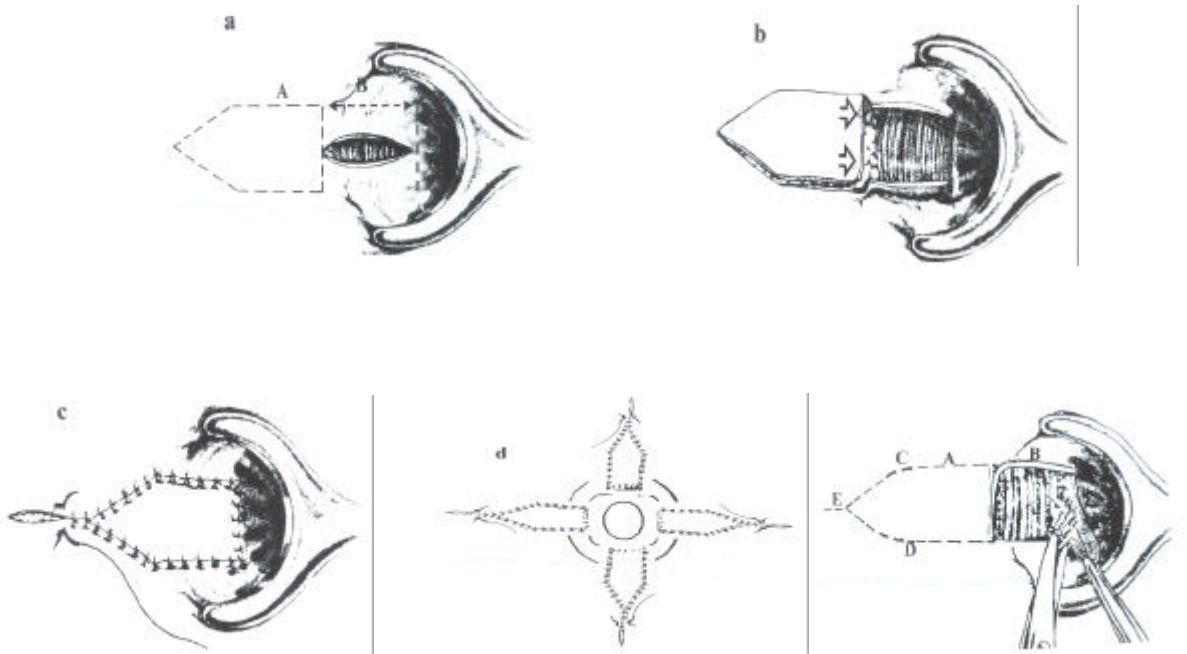


Fig. 2. House shaped advancement flap.⁸ A longitudinal incision is made laterally for the length of the anal canal. Proximal and distal incisions, centered on the ends of the longitudinal incision (a). After undermining the wound edges, it assumes a rectangular shape (b). The completed house shaped flap is advanced, lining the entire length of the anal canal, and sutured in place (c). House shaped advancement flap can be performed at 4 directions in severe stenosis (d) Author's modified house shaped advancement flap (e).

12)

가 (Good), (Fair), (Poor) Milsom⁹ 가 가

4

64 78% 4,10-12 11 10 (91%) 1 (9%)

C 6

3 , 1 ,

1 , 1

(house) 6

3 , 2 ,

1 (Table 6).

Table 5. Complication

| Complication | No of cases (%) | |
|----------------|-----------------|-----------------------------------|
| | C-anoplasty (%) | House shaped advancement flap (%) |
| Flap infection | 1 (17%) | — |
| Flap necrosis | 1 (17%) | — |
| Total | 2 (34%) | 0 |

Table 6. Result of operation

| Result | C-anoplasty | | | House shaped advancement flap | | |
|----------|-------------|------|------|-------------------------------|------|------|
| | Good | Fair | Poor | Good | Fair | Poor |
| Moderate | 3 | 1 | — | 3 | 2 | — |
| Severe | 1 | — | 1 | 1 | — | — |
| Total | 4 | 1 | 1 | 4 | 2 | — |

2 가 16
 가 16
 5 가
 가 9 (82%),

2 (18%)

가

1 2 (Little finger)
 (Index finger)
 13

C 가
 Y-V
 (house)
 1948 Penn¹⁵
 Nickell¹⁶

Y
V

V

V

Caplin Kodner¹⁷가
 가

5.8

가

Sarner¹⁸ 1969

2 3 , 4

(Fig. 3).

1992 Christensen Sarner

가
가

가

가

Ferguson¹⁴

S C

S 1959

가

가
가
가

Oh⁵ 1982 S

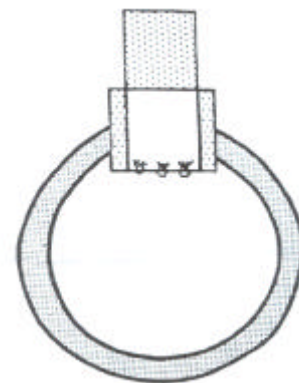


Fig. 3. Rectangular advancement flap.¹⁸

(house)
S- C-

, Y-V

, , ,
, ,

가

가 2 3 , 4

가

가

. Sarner

,
,

가

가

Christensen

Chri-

stensen

1992 1 1999 12

(Fig. 2e).

11

C

가

1

C

6

6

(Fig. 2e C,D)

releasing incision (Fig. 2e

가

C

E)

dog ear

Christensen

가

, Fig. 2a A B

A가 B

가

가

A

(Fig.

가 B

2e). Christensen

가

C

C

가

가

2 3

4

(Fig. 2d).

C

S

가

2 3 , 4

가
가

REFERENCES

1. Corman ML. Colon and Rectal surgery 4rd ed. Philadelphia • New York. Lippincott-Raven, 1997. p. 190-7.
2. Mazier WP, Levien DH, Luchtefeld MA. Surgery of the Colon, Rectum, and Anus, 1st ed. 340, Saunders, Philadelphia, 1995.
3. , , .
1987;32:103-8.
4. , .
1986;30:364-70.
5. Oh C, Zinberg J. Anoplasty for anal stricture. Dis Colon Rectum 1982;25:809-10.
6. , . C-
1993;9:1-7.
7. , , , .
C- 1986;30:762-6.
8. Christensen MA, Pitsch RM Jr, Cali RL, Blatchford GJ, Thorson AG. House advancement pedicle flap for anal stenosis. Dis Colon Rectum 1992;35:201-3.
9. Milsom JW, Mazier WP. Classification and management of postsurgical anal stenosis. Surg Gynecol Obstet 1986; 163:60-4.
10. , , .
1994;10:79-85.
11. , , .
1994;10:323-31.
12. , .
1986;30:125-31.
13. MacDonald A, Simth A, Mceill AD, et al. Manual dilatation of the anus. Br J Surg 1992;79:1381.
14. Ferguson JA. Repair of "Whitehead deformity" of the anus. SGO 1959;108:115-6.
15. Penn JA. A case of anal reconstruction by means of local skin flaps. Br J Plat Surg 1948;1:87.
16. Nickell WB, Woodward ER. Advancement flap for treatment of anal stricture. Arch Surg 1972;104:224-33.
17. Caplin DA, Kodner IJ. Repair of anal stricture and mucosal ectropion by simple flap procedures. Dis Colon Rectum 1986;29:92-4.
18. Sarnar JB. Plastic relief of anal stenosis. Dis Colon Rectum 1969;12:277-80.