

# Paget 1

가

## A Case of Recurrent Perianal Paget's Disease

Sang Young Bang, MD, Won Kyung Kang, MD, Jong Kyung Park, MD, Ji Yeon Kim, MD, Seung Chul Pa MD, Chang Hyuk Ahn, MD, Seong Taek Oh, MD

Department of Surgery, College of Medicine, The Catholic University of Korea, Seoul, Korea

Extramammary Paget's disease is an uncommon epithelial carcinoma of the skin and mucosa usually ring in the anogenital area. Perianal Paget's disease entity, often associated with internal malignancy, poor prognosis. Clinical manifestations of perianal disease include pruritis (most common), irritation lump sensation and the lesion shows erythematous, cr or scaly area which may weep clear fluid. Lichenified kokeratotic or leukoplakia-like patches may also de some patients. These areas may resemble eczema contact dermatitis. Many authors recommend surger the treatment of choice. Extended surgical excis non-invasive lesion and excision of rectum or abdo perineal resection for invasive disease is recom The prognosis for non-invasive lesion is excellent invasive lesion is poor.

We experienced one case of perianal Paget's disease recurred after wide excision of vulvar area for Page ease, and performed secondary abdominoperineal resece Now, radiation therapy was done for adjuvant therap nodality. J Korean Soc Coloproctol 2001;17: 346-3

**Key Words :** Paget's disease, Recurrent, Anus  
Paget , ,

1889 Crocker<sup>2</sup> Paget (extramammary . Paget  
Paget's disease)  
1893 Darier Couillaud<sup>3</sup>가  
100 40  
Papillary growth (erythematous plaque)  
가

70

Paget 1

1874 James Paget

: , 505  
가 : , , 70  
( : 137-701) : 1  
Tel: 02-590-1436, 3480, Fax: 02-595-2992 : 4 , 1  
E-mail: stoh@cmc.cuk.ac.kr  
가

Paget

1 cm : 6.5×3.5 cm

23 cm, 0.5 cm

Paget cell

, 1  
가 : 10  
가 : 4  
Paget  
40 cGy 5

(Fig. 1),  
가 (Fig. 2).

가 2,600/mm<sup>3</sup> (Seg 69.75%)

X

가

가

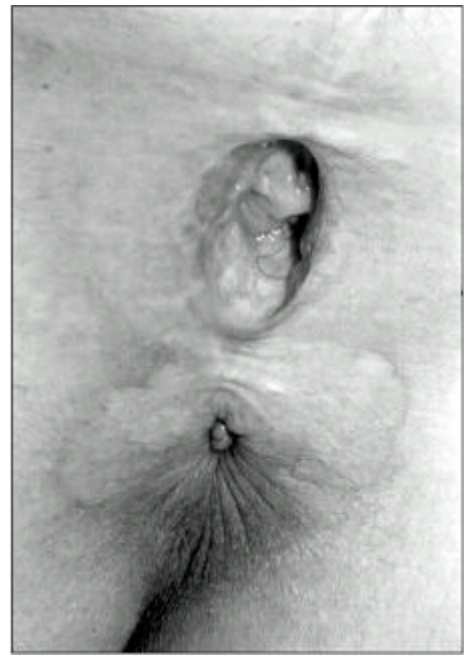

Fig. 2. Patient with perianal Paget's disease. A well-demarcated pale eczematoid lesion measuring 6.5×3.5 cm is seen around the anus.

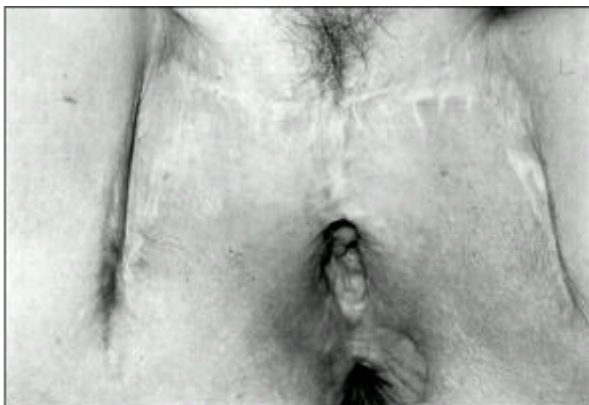

Fig. 1. Patient with perianal Paget's disease. The previous operative scar (wide vulvectomy with skin flap) is seen on the perineum.

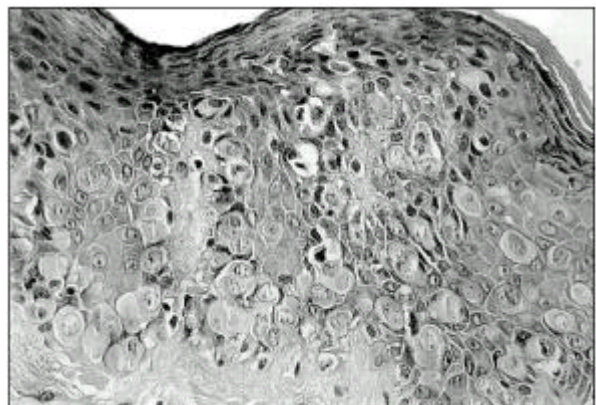


Fig. 3. Histologic finding of the perianal Paget's disease (H&E stain, ×400). Paget's cells which contain large cytoplasmic fluid are mainly seen in the epidermal layer.

Paget

14

tropic)

(Fig. 3).

(vacuolated cell)가  
가

1874 James Paget<sup>1</sup>

(basal lamina)

<sup>10,11</sup>

Paget

acid-Schiff

periodic  
cytokeratins

(carcinoembryonic antigen)

가

(intra-

가

ductal carcinoma in situ)  
(invasive carcinoma)

가

c-Erb-2

가

<sup>5,10</sup> 1889

Crocker<sup>2</sup>

<sup>12</sup>

Fenn

Paget

Paget

<sup>13,14</sup>

70%

가

Paget

1893

Darier

Coulillaud<sup>3</sup>

6 8

100

가

, Bowen  
(des),  
(ma)

(mycosis fungoi-  
(superficial basal cell carcino-  
ma)가

40

<sup>4,11</sup>

CEA

Paget

GCDFP

20%

Paget

가

가

<sup>15,16</sup>

Butler<sup>16</sup>

. Besa<sup>17</sup>

<sup>8,9</sup>

65

, 36 66%가

(lichenified),

가

(leukokeratotic patch)

(leukoplakia-like patch)

<sup>4,10</sup>

가

Paget

(epidermo-

50

cGy 50 cGy

가

Paget

가

가

가

가

Paget

70

Paget 1

## REFERENCES

1. Paget J. On disease of the mammary areola preceding cancer of the mammary gland. *St Barth Hosp Rep* 1874; 10:87-9.
2. Pitman GH, McCarthy JG, Perzin KH. Extramammary Paget's disease. *Plast Reconstr Surg* 1982;69:238-44.
3. Darier J, Coullillaud P. Sur un cas de maladie de Paget de la region perineo-anale et scrotale. *Ann Dermatol*

*Syph* 1893;4:25-33.

4. Amin R. Perianal Paget's disease. *Br J Radiol* 1999;72: 610-2.
5. Ashikari R, Park K, Huvos AG. Paget's disease of the breast. *Cancer* 1970;26:680-5.
6. Hart WR, Millman JB. Progression of intraepithelial Paget's disease of the vulva to invasive carcinoma. *Cancer* 1977;40:2333-7.
7. Merot Y, Mazoujian G, Pinkus G. Extramammary Paget's disease of the perianal and perineal regions. *Arch Dermatol* 1985;121:750-2.
8. Boehm F, Morris JM. Paget's disease and apocrine gland carcinoma of the vulva. *Obstet Gynecol* 1971;38:185-92.
9. Helwig EB, Graham JH. Anogenital (extramammary) Paget's disease: a clinicopathologic study. *Cancer* 1963;16: 387-403.
10. Jennifer A, Brainard, William R. Proliferative epidermal lesions associated with anogenital Paget's disease. *Am J Surg Pathol* 2000;24:543-52.
11. 1988;35:140-4.
12. Wolber RA, Dupuis BA, Wick MR. Expression of c-erbB-2 oncoprotein in mammary and extramammary Paget's disease. *Am J Clin Pathol* 1991;96:243-7.
13. Arminski TC, Pollard RJ. Paget's disease of the anus secondary to a malignant papillary adenoma of the rectum. *Dis Colon Rectum* 1973;16:46-55.
14. Fenn ME, Morley GW, Abell MR. Paget's disease of the vulva. *Obstet Gynecol* 1971;38:660-70.
15. Coldiron BM, Goldsmith BA, Robinson JK. Surgical treatment of extramammary Paget's disease. *Cancer* 1991; 67:933-8.
16. Butler JD, Hershman MJ, Wilson CA, Bryson JR. Perianal Paget's disease. *J Royal Soc Med* 1997;90:688-9.
17. Besa P, Rich TA, Delclos L, Edwards CL, Ota DM, Wharton JT. Extramammary Paget's disease of the perianal skin. *Int J Radiat Oncol Biol Phys* 1992;24:73-8.
18. Jensen SL, Sjolind KE, Shokouh-Amiri MH, Hagen K, Harling H. Paget's disease of the anal margin. *Br J Surg* 1988;75:1089-92.
19. Kim JC, Kim HC, Jeong CS, Cho MK, Koh KS, Gong G, et al. Extramammary Paget's disease with aggressive behavior: a report of two cases. *J Korean Med Sci* 1999; 14:223-6.