

1

,¹ ,²

.¹ .² .

A Case of Idiopathic Megacolon Associated with Sigmoid Volvulus

.^{1,2}

Joo Jin Yeom, MD, Ji Hun Choi, MD, Ji Wong K MD, Sang Wook Kim, MD, Tae Hyeon Kim, MD, Suk Chae Choi, MD, Jung Gyun Lee, MD,¹ Ki Jung Yu MD,², Young Hb Nah, MD

1

Departments of Internal Medicine, ¹General Surgery and ²Path Wonkwang University School of Medicine, Iksan, Korea

Megacolon is an uncommon condition in which the bow is persistently of increased diameter and it is associated with long-standing constipation. Two main are recognized according to whether or not gangli present in the intermuscular plane of the rectal wal complete absence, even along a short segment of rec denotes Hirschsprung's disease. If ganglia are pre dilated bowel may be secondary to some predispos factor such as a stricture, a congenital anorectal a ity, a cauda equina lesion etc. In other instances, there may be no apparent organic reason as to why bowel should be so dilated. This latter condition is "idiopathic megacolon". We report the case of one fe patient with idiopathic megacolon. During medical nent, she was complicated with a sigmoid volvulus, we formed subtotal colectomy and cecorectal anastomosi she improved without any complication. J Korean Coloproctol 2002;18:133-136

Key Words : Idiopathic megacolon, Sigmoid volvulus

10
21 가 10
가
()
2
, 4
가
100/60 mmHg, 72 / ,
20 / , 36.5°C
4190/mm³, 10 g/dl,
163,000/mm³

Hirschsprung

(Fig. 1).

(Fig. 2)

: 344-2

(: 570-711)
Tel: 063-850-1060, Fax: 063-855-2025
E-mail: kth@wmc.wonkwang.ac.kr

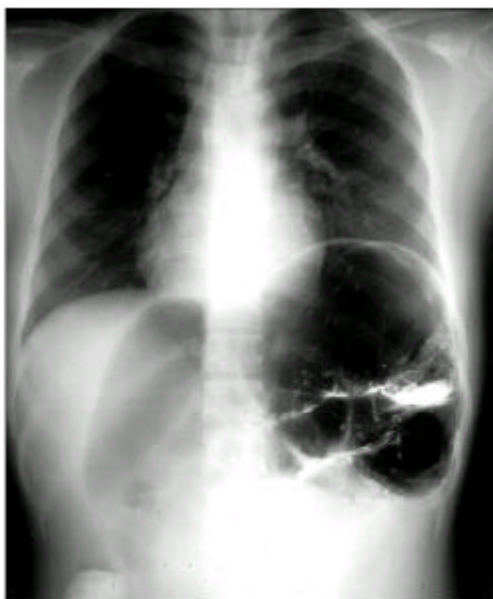

Fig. 1. Chest radiography findings. Elevation of left hemidia-
phragm due to marked dilatation of splenic flexure of colon
is noted.

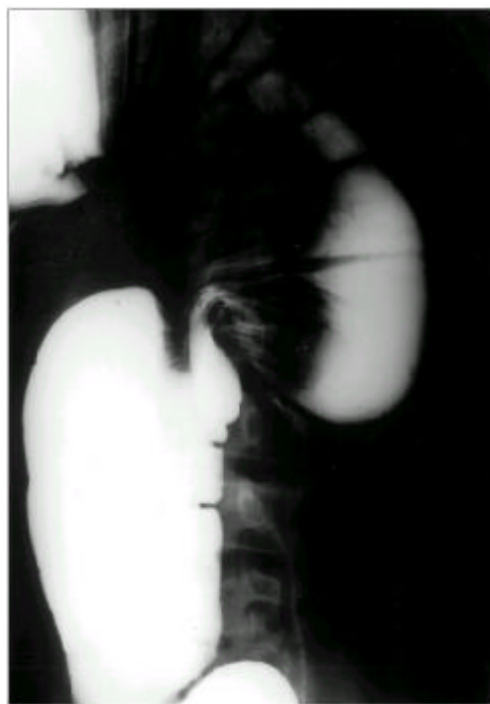

Fig. 3. Marked dilatation of proximal colonic loop due to
sigmoid volvulus is noted on follow up barium enema.

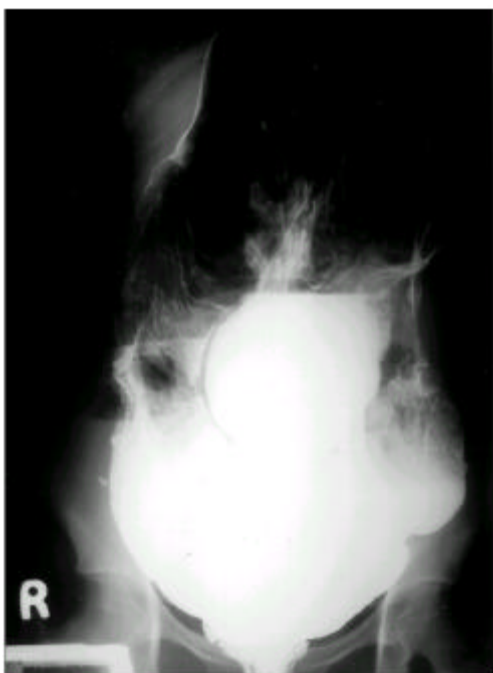

Fig. 2. Marked dilatation of colon is observed on barium
enema.

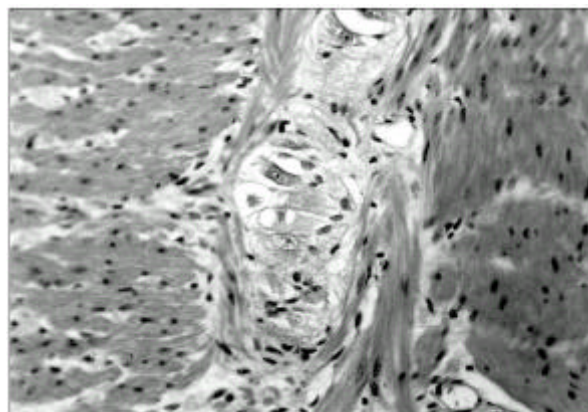


Fig. 4. Microscopic finding. The intact ganglion cells is ob-
served between inner circular and outer longitudinal muscle
layers in distal colon (H&E stain, $\times 200$).

5

(Fig. 3)

95 ml, 480 ml 가

S

(Subtotal colectomy)
(Cecorectal anastomosis)

Hirschsprung

(Fig. 4)

gastrograffin

¹⁰ Hirschsprung

가

가

8 cm

6.5 cm

12 cm

가

^{1,3,4}

Hirschsprung

가

가

⁵

, Hirschsprung

Cha-

가

gas

, 가

^{11,12}

⁶

^{10,13}

anthraquinone

Hirschsprung

, Koch ¹⁴ H&E

57%

가 1

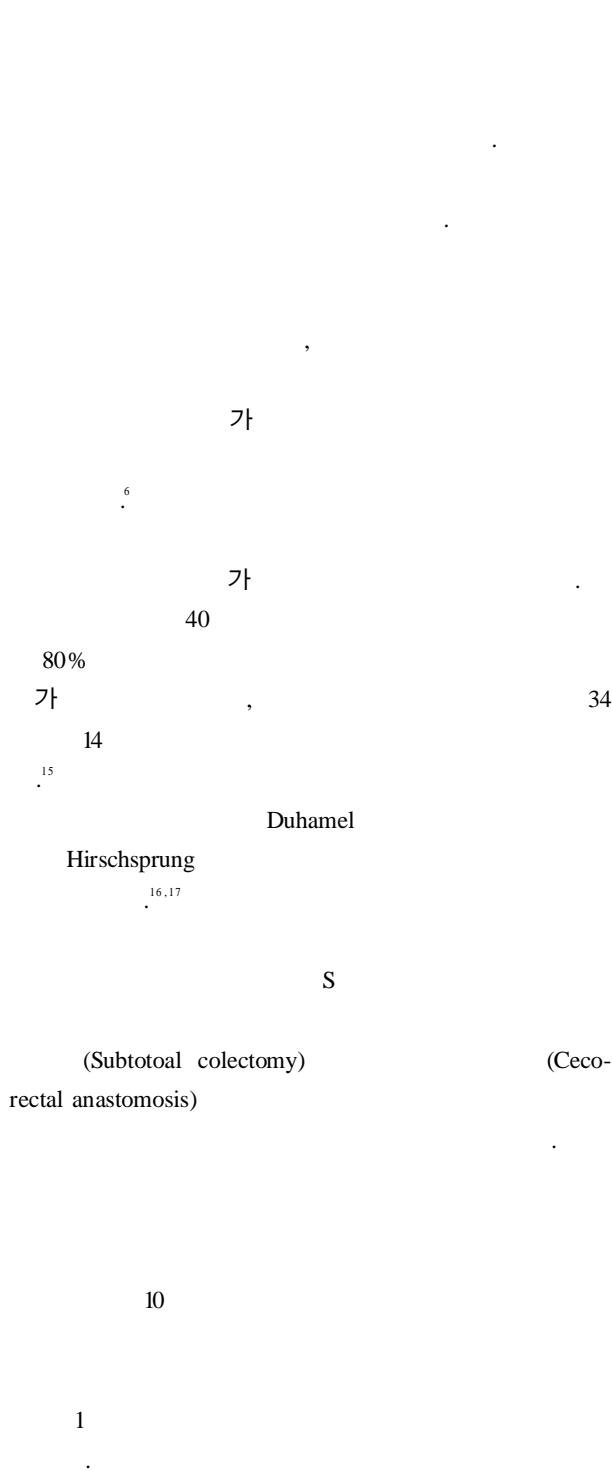
, H&E

silver

10

^{2,7}

^{8,9}



REFERENCES

1. , , , , . S

1. . 1996; 28:267-71.
2. Barnes PRH, Lennard-Jones JE, Hawley PR, Todd IP. Hirschsprung's disease and idiopathic megacolon in adults and adolescents. *Gut* 1986;27:534-41.
3. Preston DM, Lennard-Jones JE, Thomas BM. Towards a radiologic definition of idiopathic megacolon. *Gastrointest Radiol* 1985;10:167-9.
4. Tam PK. An immunochemical study with neuron-specific enolase and Substance P of human enteric innervation. The normal developmental pattern and abnormal deviations in Hirschsprung's disease and pyloric stenosis. *J Pediatr Surg* 1986;21:227-32.
5. Doig CM. Hirschsprung's disease and mimicking conditions. *Dig Dis* 1994;12:106.
6. Hagar JM, Rahimtoola SH. Chagas' heart disease in the United States. *N Engl J Med* 1991;325:763-6.
7. Oppe TE. Megacolon and megarectum in older children. *Proc R Soc Med* 1967;60:5-7.
8. Morikawa Y, Donahoe PK, Hendren WH. Manometry and histochemistry in the diagnosis of Hirschsprung's disease. *Pediatrics* 1979;63:865-72.
9. Duhamel. Histologic investigation into idiopathic Megacolon. *Arc Dis Child* 1966;41:150-1.
10. Lane RHS, Todd IP. Idiopathic megacolon : a review of 42 cases. *Br J Surg* 1977;64:305-10.
11. Todd IP. Discussion on megacolon and megarectum with the emphasis on condition other than Hirschsprung's disease. *Proc R Soc Med* 1974;54:1035-7.
12. Tobon F, Schuster MM. Megacolon: special diagnostic and therapeutic features. *Johns Hopkins Med J* 1974;135: 91-105.
13. Swenson O, Fisher JH, Macmahon HE. Rectal biopsy as an aid in the diagnosis of Hirschsprung's disease. *N Engl J Med* 1955;253:632-5.
14. Koch TR, Schulte A, Telford GL, Otterson MF, Murad TM, Stryker JJ. Idiopathic acquired megacolon is associated with alteration of enteric nervous of 42 cases. *Br J Surg* 1977;64:305-10.
15. Stabile G, Kamm MA, Hawley PR, Lennard-Jones JE. Colectomy for idiopathic megarectum and megacolon. *Gut* 1991;32:1538-40.
16. Stabile G, Kamm MA, Hawley PR, Lennard-Jones JE. Result of the Duhamel operation in the treatment of idiopathic megarectum and megacolon. *Br J Surg* 1991;78: 661-3.
17. Stabile G, Kamm MA, Lennard-Jones JE, Hawley PR. Idiopathic megarectum and megacolon: which operation offers the best results? *Gut* 1990;31:A 1172.