

Juxtaoral Organ of Chievitz – A Case Report –

Hyun Sil Kim · Jin Hak Kim¹,
In Ho Cha¹ · Tai Seung Kim²,
Mi Heon Ryu · Jin Kim

Department of Oral Pathology,
¹Department of Oral and Maxillofacial
Surgery, Yonsei University College of
Dentistry; ²Department of Pathology,
Yonsei University College of Medicine,
Seoul, Korea

Received : February 16, 2005
Accepted : April 16, 2005

Corresponding Author

Jin Kim, D.D.S
Department of Oral Pathology, Yonsei University
College of Dentistry, 134 Shinchon-dong,
Seodaemun-gu, Seoul 120-752, Korea
Tel: 02-2228-3031
Fax: 02-392-2959
E-mail: jink@yumc.yonsei.ac.kr

The juxtaoral organ of Chievitz is an intramuscular embryonic structure of neuroepithelial origin, and is found near the insertion of the pterygomandibular raphae. The juxtaoral organ of Chievitz has no known function, however, its clinical implication and differential diagnosis should be considered. Here, we report a fibrous cord like mass in a 34-year-old woman that was incidentally found while her lower right third molar was extracted. Histologically, it showed epithelial cell nests with glandular or squamous differentiation, simulating odontogenic tumors or perineural invasion of carcinoma. However, they were positive for the S-100 protein, neuron specific enolase, the neural cell adhesion molecule, and nerve growth factor receptors by immunohistochemistry, supporting the theory that these cells are of neural origin. Awareness of the juxtaoral organ of Chievitz should be emphasized for the epithelial islands in this organ not to be misinterpreted as an invasive carcinoma, an odontogenic tumor, or perineural invasion by carcinoma.

Key Words : Juxtaoral organ of Chievitz, perineural

The juxtaoral organ of Chievitz (JOC) was first described in 1885 by Chievitz, the Dutch anatomist after whom it was named.¹ He described ductless cords of epithelium which were intimately associated with the buccal nerve. The JOC is a normal neuroepithelial structure with no known function, and is typically located near the pterygomandibular raphe, between the temporal and buccinator muscles. The JOC has been misinterpreted histologically as a perineural invasion of oral carcinoma, which may sometimes lead to an unnecessarily wider surgical resection.

The purpose of this report is to draw attention to the differential diagnosis and clinical importance of this organ.

CASE REPORT

A 34-year-old woman underwent the extraction of her lower right third molar. There were no associated symptoms, except for an intermittent gingival swelling around the third molar. During extraction, the fibrous cord-like mass was noted to be

attached to the cervical portion of the tooth. Plain panoramic X-ray failed to demonstrate any lesion (Fig. 1). An incisional biopsy was performed simultaneously with the extraction of the tooth, and was submitted for histopathological evaluation.

Histologically, an area of epithelial cell nestings with no capsule formation was noted. The cell nests were composed of oval to polygonal cells showing glandular or squamous differentiation (Fig. 2A). A few cell nests showed palisading of basal cells, a characteristic which simulated an ameloblastoma (Fig. 2B). Mitosis was not detected, and the basement membrane was intact. Nerve fibers were intimately associated with the epithelial nests.

In an immunohistochemical study, the cell nests showed positive reactions with cytokeratin AE1/3 (CK AE1/3), vimentin, S-100 protein, neuron-specific enolase (NSE), neural cell adhesion molecule (NCAM) (Fig. 3A-C), and high- and low-affinity nerve growth factor receptors. Interestingly, the cell nests revealed an unexpectedly strong membrane-staining pattern with NCAM. Conversely, the cells were non-reactive for chromogranin, synaptophysin, RET, neurofilament, and protein gene product 9.5

(PGP 9.5) (Fig. 3D).

Because of its location, and the histological and immunohistochemical findings, this lesion was diagnosed as the JOC.

Six months after biopsy, the extraction socket was completely healed with neither recurrence, nor paresthesia.

DISCUSSION

The JOC is considered to be an embryonic structure, which suggests that it might be a vestigial salivary gland tissue or incidentally-included epithelium determined and incised by the direction of growth and the fusion of the maxillary and mandibular processes.² It is a strand of epithelium that appears in a 10- to 12-week-old embryo as a nodular thickening at the lateral border of the sulcus buccalis.¹ The JOC grows with the developing embryo, forming well-defined epithelial nests lying close to

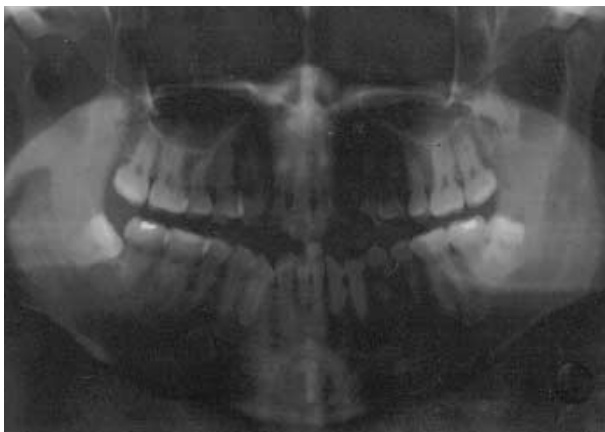

Fig. 1. There is no remarkable bony resorption around left lower third molar in panoramic X-ray view.

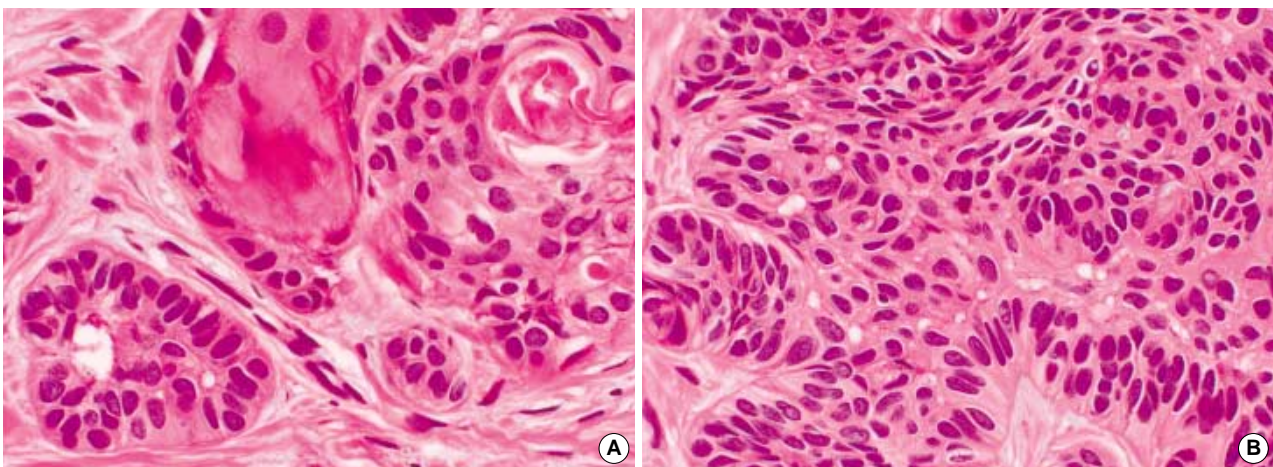


Fig. 2. The cell nests were composed of oval to polygonal cells showing glandular or squamous differentiation (A). A few cell nests showed palisading of basal cells, thereby simulating an ameloblastoma (B).

the angle of the mandible, just medial to the masseter muscle and within the medial pterygoid muscle near the insertion of the pterygomandibular raphe.

Ide assumed that neural crest influences the development of the JOC based on the presence of melanocytes within the stroma of the JOC.³ Our finding upon immunohistochemical staining with NCAM supports this hypothesis.

The incidence of the JOC has been reported to be variable. Tschén *et al.* observed the JOC in 14 of 25 consecutive adult autopsies, whereas Leibl *et al.* noted only one case in 100 autopsies.^{4,5}

The perceived function of the JOC remains controversial. It has been suggested that the JOC plays a combined role in secretory and receptor function. Some scientists have proposed its function by noting abundant enzyme activity within the parenchymal cells and a possible intimate relation to nonmyelinated nerves.⁶ As in our case, the JOC occasionally shows glandular structure,⁷ which leads us to speculate that the organ may play a specific, yet unidentified, role in endocrine function.

The immunohistochemical studies revealed that the organ was non-reactive with PGP 9.5, a marker of nerve differentiation, but was positive with NSE, a neuroendocrine marker. These results support the theory that the cells are of neural origin. However, because there are no nerve fiber bundles showing positive reactions to PGP 9.5 around the Chievitcz cell nests, it is unlikely that the JOC represents a neuroreceptor.

Awareness of this normal anatomic structure is important, because the epithelial islands in this area could be misinterpreted as an invasive cell carcinoma, an odontogenic tumor such as ameloblastoma or adenomatoid odontogenic tumor, or a perineural invasion by carcinoma. When a portion of the JOC is accidentally exposed by frozen biopsy, there is an even higher risk of mis-

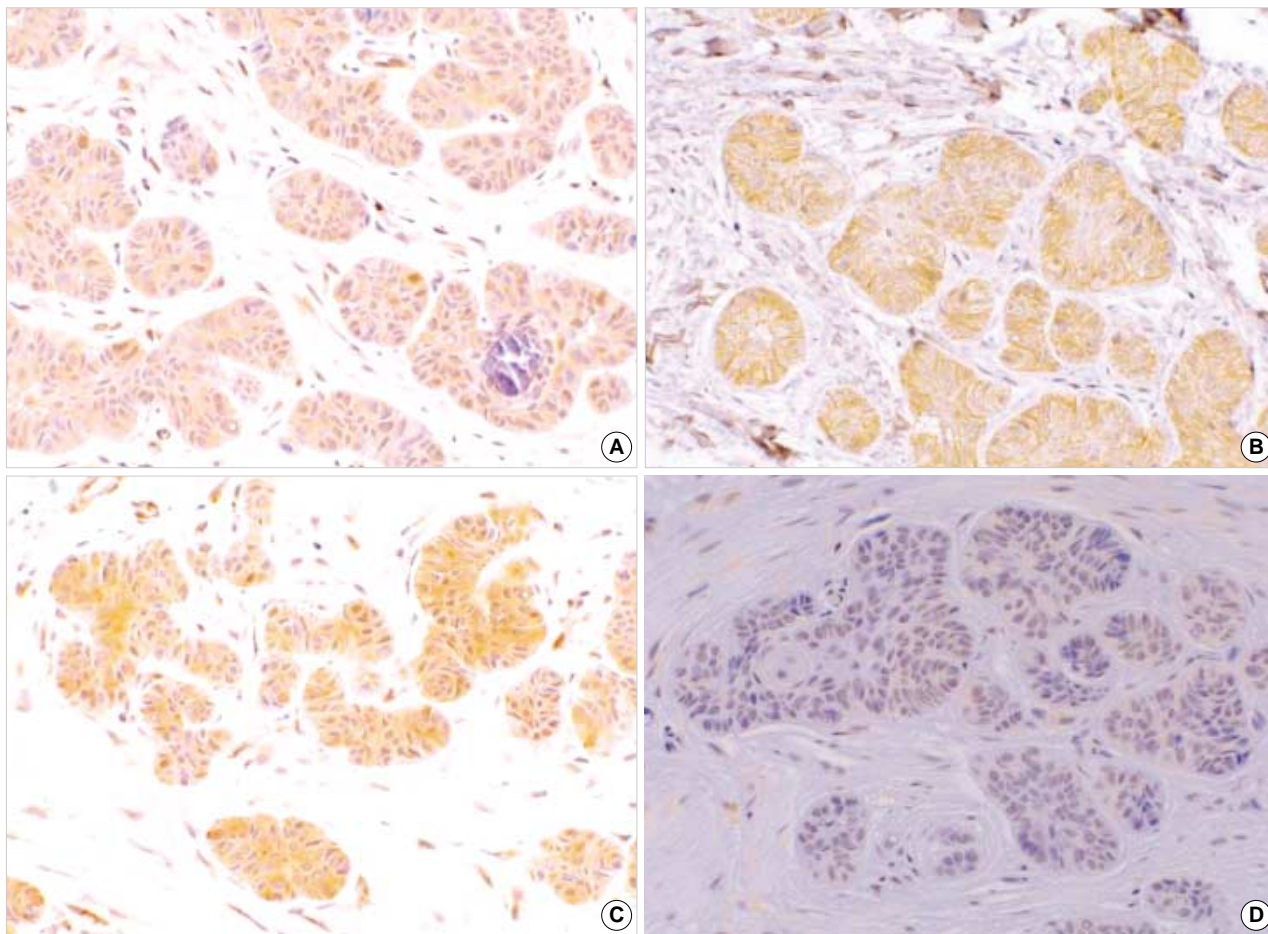


Fig. 3. Immunohistochemistry reveals the positive results for S-100 protein (A), neural cell adhesion molecule (B), and neuron specific enolase (C), but negative results for Protein Gene Product 9.5 (D).

taking these cells for an invasive cancer or a perineural invasion of carcinoma.

The JOC can be differentiated from malignancy by its benign cytological features, showing no pleomorphism, abnormal mitosis, or necrosis. The basement membrane is destroyed in carcinoma, but the basement membrane of the JOC remains intact.

Carcinoma has more disorganized and desmoplastic stroma with inflammatory reaction, while the JOC shows organized envelopment of loose and dense connective tissue stroma without inflammation.⁷

A JOC may occasionally have glandular foci filled with colloid, which is negative for mucin stain.⁷ This characteristic is distinctive from adenocarcinoma or mucoepidermoid carcinoma. The adenomatoid odontogenic tumor has also glandular structures. A fibrous capsule is easily found in an adenomatoid odontogenic tumor, but capsules are uncommon in the JOC.

The JOC is usually present behind the tooth-bearing area, deep in the medial pterygoid muscle, at the level of the ptery-

gomandibular raphe.⁸ The location may help to differentiate the JOC from odontogenic tumors, in that odontogenic epithelial cell rests can be found around tooth-bearing areas.

Numbness in the distribution of a nerve is almost pathognomonic of nerve involvement by malignancy, but it is extremely rare in the JOC. An odontogenic tumor or perineural invasion by carcinoma commonly prompts resorption of the bone which can be detected by radiologic examination. One report stated that the JOC appeared as a hamartomatous infratemporal mass associated with mandibular bony erosion.⁹ The JOC, conversely, rarely shows radiologic bony resorption.

We expect that this report will play a role in decreasing the chance of an unnecessary resection of this normal structure.

REFERENCES

1. Vadmal MS, Rossi MB, Teichberg S, Hajdu SI. Intraoral tumor of

- Chievitz in a child. *Pediatr Dev Pathol* 1998; 1: 230-3.
2. Geist ET, Adams TO, Carr RF. The organ of Chievitz: its importance in the microscopic diagnosis of oral carcinoma. *J Oral Med* 1984; 39: 177-9.
 3. Ide F, Mishima K, Saito I. Melanin pigmentation in the juxtaoral organ of Chievitz. *Pathol Int* 2003; 53: 262-3.
 4. Tschen JA, Fechner RE. The juxtaoral organ of Chievitz. *Am J Surg Pathol* 1979; 3: 147-50.
 5. Leibl W, Pfluger H, Kerjaschki D. A case of nodular hyperplasia of the juxtaoral organ in man. *Virchows Arch A Pathol Anat Histol* 1976; 371: 389-91.
 6. Zenker W, Mayr R, Widhalm S, Salzer GM. A few histochemical studies on Chievitz's Organ. *Acta Anat Basel* 1961; 45: 164-76.
 7. Pantanowitz L, Balogh K. Significance of the juxtaoral organ (of Chievitz). *Head Neck* 2003; 25: 400-5.
 8. Krammer EB, Zenker W. Letter: Neuroepithelial structures in the oral cavity. *Am J Clin Pathol* 1974; 62: 571-4.
 9. Ide F, Mishima K, Saito I. Juxtaoral organ of Chievitz presenting clinically as a tumour. *J Clin Pathol* 2003; 56: 789-90.