

Angiomyolipoma of the Nasal Cavity

Jai Hyang Go

Department of Pathology, Dankook
University College of Medicine,
Cheonan, Korea

Received : April 25, 2005
Accepted : June 20, 2005

Corresponding Author

Jai Hyang Go
Department of Pathology, Dankook University College
of Medicine, 16-5 Anseo-dong, Cheonan 330-715,
Korea
TEL: +82-41-550-6979
FAX: +82-41-561-9127
E-mail: jaihyang@yahoo.co.kr

Nasal angiomyolipomas are exceedingly rare and usually present as small tumors in middle-aged or old men. Their histology is similar to that of the renal counterpart, but they differ in the absence of epithelioid cells, the lack of HMB-45 immunoreexpression and no association with tuberous sclerosis. A case of angiomyolipoma occurring in the right nasal cavity was presented in a 44-year-old male patient. The mass was removed by an endoscopic approach. A well-circumscribed, 1.3 cm-sized, ovoid mass was composed of yellowish gray, solid, soft tissue. Histologically, it consisted of bundles of smooth muscles, mature fat cells and thick-walled blood vessels. Nests of seromucous glands were admixed within the mass. Neither epithelioid nor pleomorphic cells were found, and HMB-45-positive cells were not detected. No recurrence has been detected for 2 months after the operation.

Key Words : Nasal cavity; Hamartoma; Angiomyolipoma

Angiomyolipoma is generally a benign tumor composed of a mixture of mature fat, smooth muscle and blood vessels in various proportions.¹ These tumors usually occur in the kidney with or without tuberous sclerosis.² Nasal angiomyolipomas are exceedingly rare, and so far only six cases have been reported.²⁻⁵ They have characteristics common to other mucosal and cutaneous angiomyolipomas,^{6,7} suggesting that the tumors in these locations may be grouped as mucocutaneous angiomyolipoma and are distinguishable from renal tumors. Herein, a case of angiomyolipoma in the nasal cavity is presented.

CASE REPORT

A 44-year-old male patient was incidentally found to bear a right nasal mass, since 2 to 3 weeks ago. The past and family medical histories were unremarkable. The patient had no stigmata of tuberous sclerosis. He only complained of sore throat, and physical examination revealed a polypoid mass in the post choanal septum. A paranasal sinus computed tomography showed no enlargement of the lymph node. The polypoid mass was removed by an endoscopic approach. Grossly, a well-circumscribed, 1.3 cm-sized, ovoid mass was composed of yellowish gray, solid, soft tissue. Histologically, the mass was covered by respi-

ratory epithelium (Fig. 1). The mass predominantly consisted of bundles of smooth muscles and mature fat cells. Thick-walled blood vessels were also found. Peculiarly, nests of seromucous glands were admixed within the mass (Fig. 2). Neither epithelioid nor pleomorphic cells were found. Smooth muscles were positive for smooth muscle actin and fat cells were positive for S-100 protein on immunostaining, but HMB-45-positive cells were not found. The post-operative course has been uneventful for 2 months of available follow up.

DISCUSSION

Hamartomas of the sinonasal region are exceedingly rare.¹ Nasal hamartomas may be composed of mesenchymal or epithelial tissue. Mesenchymal hamartomas are more common and depending on the nature of the mesenchymal elements they have been termed as lipomatous, chondroid, angiomatous, or chondromesenchymal.¹ Epithelial predominant hamartomas are characterized by tissues indigenous to the nasal region including surface epithelium, fibrous stroma, and seromucinous glands.^{1,8} Respiratory epithelial adenomatoid hamartoma has demonstrated a predominant glandular pattern arising from the surface respiratory epithelium.¹

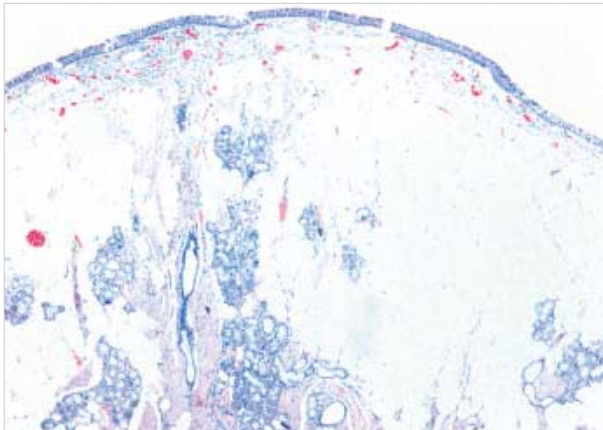


Fig. 1. The nasal mass was covered by respiratory type of epithelium.

Angiomyolipoma is a generally benign tumor composed of a mixture of mature fat, smooth muscle and blood vessels in various proportions.¹ These tumors usually occur in the kidney with or without tuberous sclerosis, but are capable of occurring anywhere in the body as a vascular hamartoma.⁴ Angiomyolipoma in tissues other than the kidney and liver is rare, and only a few cases in the mediastinum, heart, spermatic cord, vaginal wall, fallopian tube, oral cavity, pharynx and skin have been reported.²

Intranasal localization of angiomyolipoma is exceedingly rare. The histological composition of this tumor comprises vascular, smooth muscle and adipose elements, which are intimately admixed, qualifying the tumor an inclusion within hamartomas.^{4,5}

So far, only six cases of angiomyolipomas of the nasal cavity have been reported.²⁻⁵ Including the present case, the patients were five men and two women with an age range of 44-88 years. Six tumors were located in the right nasal cavity and one in the left cavity. The tumors measured between 13 and 40 mm. It appears that nasal angiomyolipomas usually present as small tumors preferentially in middle-aged or old men. The histology was very uniform in all of them and similar to that of the renal counterpart. Differences from the renal tumors are the absence of epithelioid cells, the lack of HMB-45 immunoreaction^{2,5} and no association with tuberous sclerosis. These characteristics are common to other mucosal and cutaneous angiomyolipomas,^{6,7} suggesting that the tumors in these locations may be distinct from renal and hepatic tumors, in which epithelioid smooth muscle cells exhibit HMB45 immunoreactivity and commonly have melanosome-like dense granules in their cytoplasm and are considered to be perivascular epithelial cells.²

A peculiar finding in this case was the presence of dispersed seromucous glands within the mass, thus raising a possibility

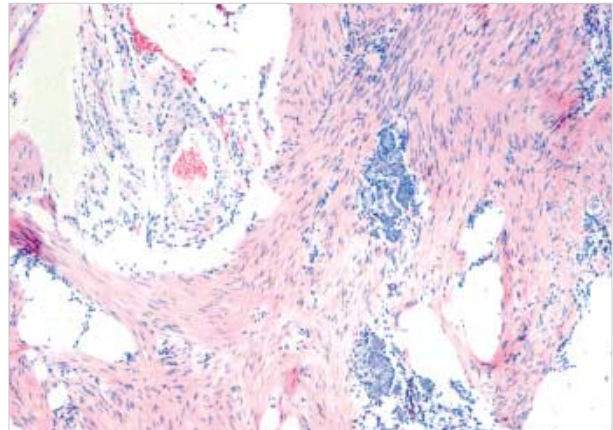


Fig. 2. The mass consisted of bundles of smooth muscles, mature fat cells and thick-walled blood vessels. Nests of seromucous glands were admixed within the mass.

of coexisting epithelial hamartomatous components. However, a seromucinous gland component is considered a reactive or hyperplastic response even in cases of respiratory epithelial adenomatoid hamartoma.^{8,9}

Hamartomas are benign and self-limited lesions and recurrences have not been documented in the nasal angiomyolipoma.^{2,4} Therefore, a complete surgical excision is the treatment of choice. When the hamartoma is limited to the nasal cavity, it is often amenable to an endoscopic surgery,¹ as in the present case.

REFERENCE

1. Norman ES, Bergman S, Trupiano JK. Nasal chondrom esenchymal hamartoma: report of a case and review of the literature. *Pediatr Dev Pathol* 2004 7: 517-20.
2. Watanabe K, Suzuki T. Mucocutaneous angiomyolipoma. A report of 2 cases arising in the nasal cavity. *Arch Pathol Lab Med* 1999; 123: 789-92.
3. Tardio JC, Martin-Fragueiro LM. Angiomyolipoma of the nasal cavity. *Histopathology* 2002; 41: 174-5.
4. Dawlatly EE, Anim JT, el-Hassan AY. Angiomyolipoma of the nasal cavity. *J Laryngol Otol* 1988; 102: 1156-8.
5. Gatalica Z, Lowry LD, Petersen RO. Angiomyolipoma of the nasal cavity: case report and review of the literature. *Head Neck* 1994; 16: 278-81.
6. Piattelli A, Fioroni M, Rubini C, Fiera E. Angiomyolipoma of the palate. Report of a case. *Oral Oncol* 2001; 37: 323-5.
7. Val-Bernal JF, Mira C. Cutaneous angiomyolipoma. *J Cutan Pathol* 1996; 23: 364-8.
8. Zarbo RJ, Torres FX, Gomez J. Nasal cavity and paranasal sinuses.

In: Pilch BZ, editor. Head and neck surgical pathology. Philadelphia: Lippincott Williams and Wilkins; 2002: 103-4.

9. Delbrouck C, Fernandez Aguilar S, Choufani G, Hassid S. Respira-

tory epithelial adenomatoid hamartoma associated with nasal polyposis. *Am J Otolaryngol* 2004; 25: 282-4.