

Immunohistochemical Expression of the Sodium/Iodide Symporter in Patients with Primary Lung Cancer

Hyoun Wook Lee¹ •
Do Young Kang² • Phil Jo Choi³
Doo Kyung Yang⁴ • Ki Nam Kim⁵
Kyung Eun Lee⁶ • Mee Sook Roh^{1,6}

Departments of ¹Pathology, ²Nuclear
Medicine, ³Thoracic and Cardiovascular
Surgery, ⁴Internal Medicine and
⁵Diagnostic Radiology and ⁶Medical
Research Center for Cancer Molecular
Therapy, Dong-A University College of
Medicine, Busan, Korea

Received : December 5, 2005
Accepted : February 21, 2006

Corresponding Author

Mee Sook Roh, M.D.
Department of Pathology, Dong-A University College
of Medicine, 1 3-ga, Dongdaeshin-dong, Seo-gu,
Busan 602-715, Korea
Tel: 051-240-2833
Fax: 051-243-7396
E-mail: msroh@dau.ac.kr

*This paper was supported by the Dong-A University
Research Fund in 2005.

Background : The sodium/iodide symporter (NIS) is a membrane glycoprotein that facilitates the uptake of iodine by thyroid follicular cells. Although the use of radioiodide is essential for the diagnosis and treatment of thyroid diseases, few studies have been conducted to investigate the use of NIS-mediated radioiodide accumulation in lung cancer. We evaluated the expression of NIS by immunohistochemistry in order to examine the diagnostic or therapeutic feasibility of using radioiodide in the treatment of primary lung cancer. **Methods :** Immunohistochemistry for NIS was performed in 139 lung cancers. The expression pattern of NIS was compared with the clinicopathological characteristics of the tumors. **Results :** NIS immunoreactivity was detected in 75 (54.0%) of the 139 cases. Twenty-three (37.7%) of the 61 squamous cell carcinomas, 49 (76.6%) of the 64 adenocarcinomas, 2 (40.0%) of the 5 small cell carcinomas, and 3 (33.3%) of the 9 other carcinomas showed positive NIS immunoreactivity. The expression of NIS was significantly associated with the histologic type ($p < 0.001$), but it did not correlate with tumor size, lymphovascular invasion or lymph node metastasis. **Conclusions :** The presence of NIS was detected in lung cancer tissue using immunohistochemistry. Lung cancer potentially could be targeted with radioiodide for both diagnosis and treatment, especially in cases of adenocarcinoma.

Key Words : Lung cancer; Sodium iodide symporter; Immunohistochemistry

The sodium/iodide symporter (NIS) is an intrinsic membrane glycoprotein that functions by co-transporting one I^- ion along with two Na^+ ions into cells.¹ NIS plays a key role in thyroid hormone production by efficiently accumulating iodide from the circulation into thyrocytes. This is done against an electrochemical gradient.^{2,3} The iodide-concentrating activity of the thyroid gland allows for the use of radioiodide in thyroid scintigraphy for the diagnosis of thyroid nodules, as well as for ablation of postsurgical remnants and the treatment of recurrent or metastatic thyroid cancer. Thyroidal NIS has been cloned, and NIS mRNA and protein expressions have been reported in a variety of extrathyroidal tissues, including the salivary and lacrimal glands, gastric mucosa, kidney and mammary gland, suggesting that iodide transport in these tissues is also mediated by the expression of functional NIS protein.⁴⁻⁷ It was generally thought until recently that the lack of I^- organification in the extrathy-

roidal tissues that functionally express NIS would preclude the use of radioiodide to treat cancer in these tissues. However, an important recent discovery is that NIS is functionally expressed *in vivo* in transgenic mouse mammary tumors, and NIS has been immunohistochemically detected in over 80% of human breast cancers.⁷ This raises the possibility of using radioiodide as a novel therapy for breast cancer. It also suggests that extrathyroidal NIS-expressing cancers might be targeted with radioiodide, if NIS is functionally present.

To the best of our knowledge, the NIS expression pattern in primary lung cancer has not yet been studied in Korea. We undertook this study to evaluate the expression pattern of NIS using immunohistochemistry, and to determine whether or not radioiodide might be an alternative diagnostic or therapeutic modality for treating primary lung cancer.

MATERIALS AND METHODS

Materials

We retrospectively examined 139 cases of primary lung cancer from the surgical pathology archival files of the Department of Pathology at Dong-A University Medical Center. The records were compiled from 2000 to 2004. No preoperative chemotherapy or radiotherapy had been administered in any of these cases. Standard lobectomy or pneumonectomy and lymph node dissections were performed in every case. Tissues, clinical records and pathological reports were obtained for all 139 cases. This study was approved by the institutional review board, and written informed consent was obtained from all of the subjects at the time of surgery. The hematoxylin and eosin-stained slides were reviewed in each case to confirm the original diagnosis, based on the World Health Organization (WHO) criteria.⁸

Immunohistochemical evaluation

Immunohistochemical study for NIS was performed on formalin-fixed, paraffin-embedded, 4 μ m-thick tissue sections, using the avidin-biotin-peroxidase complex method. The primary antibody was a mouse monoclonal antibody directed against NIS (Neomarkers, Fremont, CA, USA) used in a 1:50 dilution. Deparaffinization of all the sections was performed through a series of xylene baths, and rehydration was performed with a series of graded alcohol solutions. To enhance immunoreactivity, microwave antigen retrieval was performed at 750 W for 30 min in citrate buffer (pH6.0). After blocking endogenous peroxidase activity with 5% hydrogen peroxidase for 10 min, primary antibody incubation was performed for 1 hour at room temperature. Cap-PlusTM biotinylated secondary antibody (Zymed, USA) was applied for 30 min at room temperature, and then Cap-PlusTM streptavidin-HRP (Zymed, USA) was applied for 30 min at room temperature. After washing the tissue samples in Tris-buffered saline for 10 min, 3, 3'-diaminobenzidine was used as a chromogen, and Mayer's hematoxylin counterstain was applied. Tissue from a Graves' disease patient was used as a positive control.

Interpretation of immunohistochemical staining

Immunoreactivity for NIS expression was defined by the presence of granular cytoplasmic or membranous staining. The NIS staining intensity was classified as negative, weak, moderate, or

strong. A tumor was defined as NIS positive if more than 10% of the cells showed moderate or strong staining. A negative staining result was defined as weak or absent staining in any number of cells, or moderate/strong staining in less than 10% of the cells.

Statistical analysis

Statistical analysis was performed with the Statistical Package Service Solution software (SPSS for Windows, Standard version 11.0, Chicago, IL, USA). χ^2 tests were performed to assess the relationship between the staining pattern of NIS and the clinicopathological characteristics. A p value less than 0.05 was considered to be statistically significant.

RESULTS

Clinicopathological characteristics

The ages of the 139 patients ranged from 25 to 75 years (median age: 60 years), and there were 104 men and 35 women. Tumor sizes ranged from 1 cm to 11 cm (median size: 3.7 cm); 63 cases had tumors \leq 3 cm, and 76 cases had tumors $>$ 3 cm. Histologically, they consisted of 61 squamous cell carcinomas, 64 adenocarcinomas, 5 small cell carcinomas, 8 other carcinomas (3 large cell neuroendocrine carcinomas, 2 large cell carcinomas and 3 pleomorphic carcinomas) and 1 carcinosarcoma. Lymph node metastases were present in 52 of the 139 cases, and lymphovascular tumor invasion was seen in 69 of the 139 cases.

NIS expression and its relationship with the clinicopathological characteristics

Overall, NIS immunoreactivity was detected in 75 (54.0%) of the 139 cases. There was no NIS expression in normal alveolar tissue or bronchial mucous glands, and only weak and focal immunoreactivity was seen in the apical portion of the ciliated columnar cells in normal bronchial mucosa.

Twenty-three (37.7%) of the 61 squamous cell carcinomas, 49 (76.6%) of the 64 adenocarcinomas, 2 (40.0%) of the 5 small cell carcinomas and 3 (33.3%) of the 9 other carcinomas demonstrated positive NIS immunoreactivity. NIS expression was significantly associated with the histologic type ($p < 0.001$) (Fig. 1). However, there were no significant associations between NIS expression and age, sex, tumor size, lymphovascular invasion or

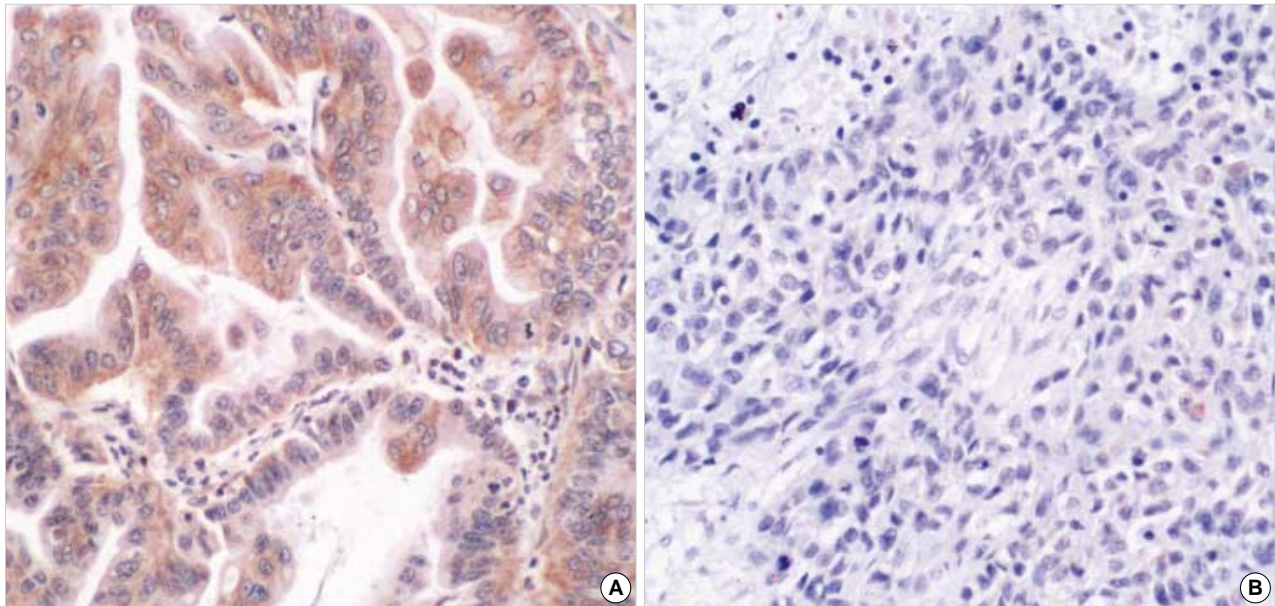


Fig. 1. Immunohistochemical studies for sodium iodide symporter show a positive cytoplasmic reaction in the adenocarcinoma (A), but a negative reaction in the squamous cell carcinoma (B).

Table 1. Relationship between the pathological characteristics and the NIS expression in 139 primary lung cancers

Pathological characteristics	No. of cases	NIS expression		p value
		Negative (%) N=64	Positive (%) N=75	
Histologic type				<0.001
Squamous cell carcinoma	61	38 (62.3)	23 (37.7)	
Adenocarcinoma	64	15 (23.4)	49 (76.6)	
Small cell carcinoma	5	3 (60.0)	2 (40.0)	
Others	9	6 (66.7)	3 (33.3)	
Tumor size				NS
≤3 cm	63	29 (46.0)	34 (54.0)	
>3 cm	76	35 (46.1)	41 (53.9)	
Lymph node metastasis				NS
Negative	87	40 (46.0)	47 (54.0)	
Positive	52	24 (46.2)	28 (53.8)	
Lymphovascular invasion				NS
Negative	70	33 (47.1)	37 (52.9)	
Positive	69	31 (44.9)	38 (55.1)	

NIS, sodium/iodide symporter; Others, 3 large cell neuroendocrine carcinomas, 2 large cell carcinomas, 3 pleomorphic carcinomas and 1 carcinosarcoma.

lymph node metastasis (Table 1).

DISCUSSION

NIS expression in normal and cancerous tissues is of keen interest because of its potential to serve as a specific conduit for

an alternative diagnostic modality or for targeted therapeutic destruction of NIS-expressing malignant cells using radioiodide. Experimentally, NIS has been either transfected and/or transferred with an adenoviral or retroviral vector to test the concept of targeted ablative therapy. Novel evidence in prostate cancer cells that express exogenous NIS after adenoviral gene transfer has convincingly shown that a prolonged retention time and potential therapeutic efficacy for ^{131}I are achievable in NIS-expressing extrathyroidal cells, even in the absence of I^- organification.⁹ Evaluating NIS expression is helpful for predicting the effectiveness of radioiodide therapy, and it has the potential of enhancing patient management. Min *et al.*¹⁰ have reported that NIS immunohistochemical staining predicted ^{131}I uptake in recurrent thyroid cancer with 50% sensitivity and 100% specificity, and that it showed a high positive predictive value for iodine uptake. Castro *et al.*¹¹ have also reported that NIS immunostaining of primary thyroid tumors in patients with papillary and follicular thyroid cancers is useful for predicting the iodine trapping and concentration behavior of subsequent deposits of metastatic or recurrent cancer.

The ability of thyroid cancers to concentrate radioiodine is dependent, at least in part, upon the expression and functional integrity of the NIS. Compared with the thyroid gland, extrathyroidal tissues have a much lower ability to transport and concentrate iodide. Because identical NIS proteins are encoded in thyroid and extrathyroidal tissues, the diminished iodide transport seen in the extrathyroidal tissues may result from altered

NIS gene transcriptional activity. This could be a consequence of altered promoter structure or function, or the result of altered *NIS* mRNA or protein turnover.⁴ The variable and lower *NIS* transcriptional activity in the extrathyroidal tissues may be accounted for, at least in part, by thyroid-specific transcription factors that act on the *NIS* promoter to control the *NIS* gene expression in the thyroid gland. Thyroid transcription factor 1 (TTF-1) is a homeodomain-containing protein. It has been found to bind to all three thyroid-specific promoters and to activate their transcriptional activity.¹² Spitzweg *et al.*⁴ have suggested that TTF-1 may be one of the factors capable of activating *NIS* gene expression in the thyroid gland, its absence thus accounting for the lower levels of *NIS* gene expression seen in extrathyroidal tissues. In lung cancer, a high frequency of TTF-1 expression has been observed in adenocarcinoma (75-80%), whereas squamous cell carcinomas and large cell carcinomas showed no, or low, TTF-1 expression.¹³ In our study, *NIS* expression was significantly higher in tissues of lung adenocarcinoma than in the other histologic types. These findings suggest that TTF-1 may be one of the factors capable of activating *NIS* gene expression in adenocarcinomas, and that its absence accounts for the lower levels of *NIS* expression in the other histologic types of lung cancer. However, small cell carcinomas, which usually have a high frequency of TTF-1 expression, showed only 40% *NIS* expression in our study. This may have been partially due to the small number of cases. Further studies are needed to more accurately determine the relation between *NIS* and TTF-1 for examining the mechanisms of tissue-specific *NIS* expression.

Positron emission tomography (PET) imaging using ¹⁸F-2-fluoro-2-deoxy-D-glucose (¹⁸F-FDG) has become an important non-invasive technique for evaluating focal pulmonary abnormalities, for staging lung cancer and for detecting recurrent neoplasms. ¹⁸F-FDG uptake is known to be closely related to the over-expression of Glut-1 in human cancers, including lung cancer.¹⁴ However, Glut-1 expression is lower in adenocarcinomas than in squamous cell carcinomas or large cell carcinomas of the lung.¹⁵ Lazar *et al.*¹⁶ have reported that 3 patients with normal Glut-1 gene expression also had ¹³¹I uptake in their metastatic lesions, whereas the other 3 patients with increased Glut-1 gene expression had no detectable ¹³¹I uptake. In our study, *NIS* expression was significantly higher in the adenocarcinomas compared to the other histologic types of tumors. Although we did not compare the expression patterns of Glut-1 and *NIS*, our findings may provide a rationale and biological basis for a role for PET and radioiodide scanning in the clinical management of lung cancer. We suggest that when immunohistochemical stain-

ing for *NIS* is positive, but the immunohistochemical staining for Glut-1 is negative, the most reliable imaging study might be the radioiodide scan, especially for evaluation of adenocarcinoma of the lung.

Although use of these radioisotopes has long been essential in the diagnosis and treatment of thyroid diseases, a few important factors need to be considered if radioiodide therapy is to be used with extrathyroidal tissues: 1) the degree of iodide transporting activity; 2) the ability of cells to accumulate and retain radioisotope, so as to effectively deliver its radiation dose, even in the absence of I⁻ organification; and, 3) the need to block the avid trapping of I⁻ by the intact thyroid gland.¹⁷ It should also be emphasized that the demonstration of *NIS* expression in a given tissue solely by immunohistochemistry does not necessarily mean that the *NIS* is functional in that tissue.

In conclusion, we have shown that *NIS* can be detected in lung cancers using immunohistochemistry, especially in adenocarcinoma of the lung. These findings may provide a helpful foundation for examining the potential clinical utility of radioiodide in evaluating and treating primary lung cancer. However, researchers will need to further define the regulatory mechanisms that render the *NIS* functional in tissues of lung cancer, so as to make the use of radionuclides feasible in the diagnosis or treatment of such patients.

REFERENCES

1. Jhian SM. Regulation of sodium/iodide symporter. *Rev Endocr Metab Disord* 2000; 1: 205-15.
2. Trapasso F, Iuliano R, Chiefari E, *et al.* Iodide symporter gene expression in normal and transformed rat thyroid cells. *Eur J Endocrinol* 1999; 140: 447-51.
3. Filetti S, Bidart JM, Arturi F, Caillou B, Russo D, Schlumberger M. Sodium/iodide symporter: a key transport system in thyroid cancer cell metabolism. *Eur J Endocrinol* 1999; 141: 443-57.
4. Spitzweg C, Joba W, Eisenmenger W, Heufelder AE. Analysis of human sodium iodide symporter gene expression in extrathyroidal tissues and cloning of its complementary deoxyribonucleic acids from salivary gland, mammary gland, and gastric mucosa. *J Clin Endocrinol Metab* 1998; 83: 1746-51.
5. Spitzweg C, Joba W, Schriever K, Goellner JR, Morris JC, Heufelder AE. Analysis of human sodium iodide symporter immunoreactivity in human exocrine glands. *J Clin Endocrinol Metab* 1999; 84: 4178-84.
6. Spitzweg C, Dutton CM, Castro MR, *et al.* Expression of the sodium iodide symporter in human kidney. *Kidney Int* 2001; 59: 1013-23.

7. Tazebay UH, Wapnir IL, Levy O, *et al.* The mammary gland iodide transporter is expressed during lactation and in breast cancer. *Nat Med* 2000; 6: 871-8.
8. Travis WD, Brambilla E, Muller-Hermelink HK, Harris CC. World Health Organization International Histological Classification of Tumours. Pathology and genetics of tumors of the lung, pleura, thymus and heart. In: Colby TV, Noguchi M, eds. *Adenocarcinoma*. 4th ed. Lyon: IARC Press, 2004: 35-44.
9. Spitzweg C, O'Connor MK, Bergert ER, Tindall DJ, Young CY, Morris JC. Treatment of prostate cancer by radioiodine therapy after tissue-specific expression of the sodium iodide symporter. *Cancer Res* 2000; 60: 6526-30.
10. Min JJ, Chung JK, Lee YJ, *et al.* Relationship between expression of the sodium/iodide symporter and ¹³¹I uptake in recurrent lesions of differentiated thyroid carcinoma. *Eur J Nucl Med* 2001; 28: 639-45.
11. Castro MR, Bergert ER, Goellner JR, Hay ID, Morris JC. Immunohistochemical analysis of sodium iodide symporter expression in metastatic differentiated thyroid cancer: correlation with radioiodine uptake. *J Clin Endocrinol Metab* 2001; 86: 5627-32.
12. Saiardi A, Tassi V, De Filippis V, Civitareale D. Cloning and sequence analysis of human thyroid transcription factor 1. *Biochim Biophys Acta* 1995; 1261: 307-10.
13. Zamecnik J, Kodet R. Value of thyroid transcription factor-1 and surfactant apoprotein A in the differential diagnosis of pulmonary carcinomas: a study of 109 cases. *Virchows Arch* 2002; 440: 353-61.
14. Higashi K, Ueda Y, Sakurai A, *et al.* Correlation of Glut-1 glucose transporter expression with [¹⁸F] FDG uptake in non-small cell lung cancer. *Eur J Nucl Med* 2000; 27: 1778-85.
15. Brown RS, Leung JY, Kison PV, Zasadny KR, Flint A, Wahl RL. Glucose transporters and FDG uptake in untreated primary human non-small cell lung cancer. *J Nucl Med* 1999; 40: 556-65.
16. Lazar V, Bidart JM, Caillou B, *et al.* Expression of the Na⁺/I⁻ symporter gene in human thyroid tumors: a comparison study with other thyroid-specific genes. *J Clin Endocrinol Metab* 1999; 84: 3228-34.
17. Wapnir IL, van de Rijn M, Nowels K, *et al.* Immunohistochemical profile of the sodium/iodide symporter in thyroid, breast, and other carcinomas using high density tissue microarrays and conventional sections. *J Clin Endocrinol Metab* 2003; 88: 1880-8.