

Green Teeth Associated Hyperbilirubinemia in Primary Dentition

Min Kyung Park^{1†}, Yeji Sun^{1†}, Chung-Min Kang¹, Hyo-Seol Lee², Je Seon Song¹

¹*Department of Pediatric Dentistry, College of Dentistry, Yonsei University*

²*Department of Pediatric Dentistry, College of Dentistry, Kyung-Hee University*

Abstract

There are many reasons for tooth discoloration. An increase in the bilirubin level may cause tooth discolorations. Such cases are rare, but most involve tooth discoloration with a greenish hue.

The purpose of this case report is to describe green discoloration of the primary dentition in the presence of neonatal hyperbilirubinemia. 2 boys aged 16 and 22-months presented with chief complaints of erupting teeth of abnormal color. Their primary teeth exhibited a greenish discoloration along enamel hypoplasia. Both patients were born prematurely with a low birth weight and had been diagnosed with neonatal hyperbilirubinemia.

Systematic diseases can affect the hard tissue of teeth during their formation and result in changes in tooth color. Periodic follow-ups are required for establishing a normal dental condition and meeting the esthetic needs of patients. A pediatric dentist may be the first person to observe patients with discoloration in their primary dentition. In such cases the dentist can deduce the systematic disease responsible for this discoloration.

Key words : Green teeth, Intrinsic discoloration, Hyperbilirubinemia, Bilirubin

I. Introduction

There are many reasons for tooth discoloration, which can be classified into extrinsic and intrinsic according to the inducing factor. Extrinsic tooth discoloration is caused by the accumulation of causative materials on the tooth surface, and so it can be removed. Such causes include beverage (e.g., coffee and tea) food, oral hygiene, bacteria, smoking, oral rinses (chlorhexidine), and metals (e.g., copper, nickel)[1-4]. In contrast, intrinsic tooth discoloration is caused by metabolic disorders, anomalies of the developing dental follicle, genetic factors, drug administration, and fluorosis. Because these caus-

ative materials infiltrate into the tooth structure, their removal is impossible[5-8]. Tooth discoloration can be an esthetic problem, and it is one of main reasons why patients visit dentists.

Jaundice of the newborn infant is common due to immature kidney metabolism resulting in elevated blood bilirubin. Jaundice appears clinically when the level of blood bilirubin exceeds over 7.0 mg/dL. Treatment for physiologic jaundice is necessary only in underweight premature babies[9-11]. An increase in the bilirubin level may cause tooth discolorations[5]. Such cases are rare, but most involve tooth discoloration with a greenish hue[12,13].

The aim of this report is to describe 2 pediatric patients

Corresponding author : Je Seon Song

Department of Pediatric Dentistry, College of Dentistry, Yonsei University, 50-1 Yonsei-ro, Seodaemun-gu, Seoul, 03722, Korea

Tel: +82-2-2228-3176 / Fax: +82-2-392-7420 / E-mail: SONGJS@yuhs.ac

Received October 20, 2016 / Revised November 25, 2016 / Accepted November 15, 2016

† These authors equally contributed to this work.

with tooth discoloration associated with hyperbilirubinemia who visited the Yonsei University Dental Hospital having green teeth as the chief complaint.

II. Case Reports

Case 1

A 22-month old male visited the Department of Pediatric Dentistry, Yonsei University Dental Hospital due to tooth discoloration. A clinical oral examination revealed that the primary central and lateral incisors (with the exception of the lower right lateral incisor) were erupted, and that the primary lower first molars were partially erupted. These teeth showed green discoloration, and the upper central teeth exhibited enamel hypoplasia (Fig. 1).

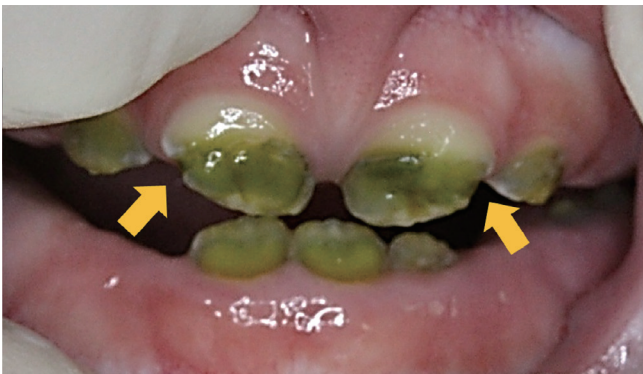

Fig. 1. Green discoloration of teeth in a 22-month-old boy. Enamel hypoplasia was evident on the primary upper central incisors (yellow arrows).

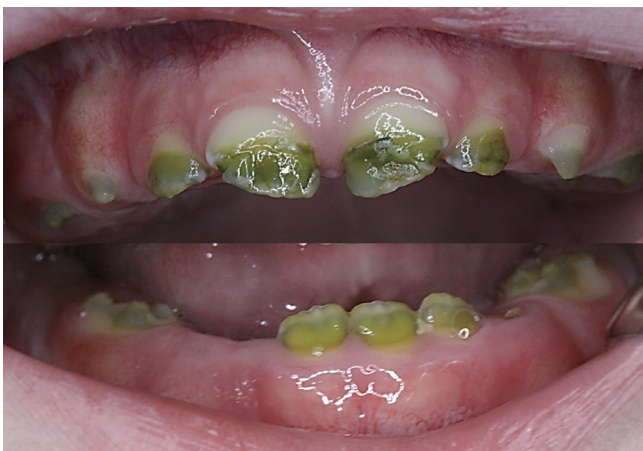

Fig. 2. Green discoloration of teeth at 3 months after the first visit.

Owing to chorioamnionitis, the patient was born prematurely after 25 weeks and 6 days of gestation, weighing only 750 g. The patient received intubation in an incubator due to perinatal asphyxia. At birth the patient suffered from a neonatal seizure and was diagnosed with periventricular leukomalacia and cerebral palsy. The patient also received phototherapy for 1 week, due to neonatal hyperbilirubinemia.

After 3 months, primary upper canines and first molar and lower left canine could be partially observed. These teeth exhibited varying degrees of general green discoloration with the central and lateral incisors being most affected, followed by the first molars and canines. The various tooth areas exhibiting discoloration and normal hue could be easily ascertained (Fig. 2).

Case 2

A 16-month-old boy who had congenital green teeth visited the Department of Pediatric Dentistry, Yonsei University Dental Hospital. An intraoral examination revealed that the primary central and lateral incisors were partially erupted in the maxilla and mandible. These teeth appeared greenish due to intrinsic factors. The upper central incisors exhibited enamel hypoplasia bilaterally (Fig. 3).

The patient was born by Cesarean section due to an amnion rupture after 26 weeks and 6 days of gestation, weighing 930 g. The patient suffered from severe bronchial pulmonary dysplasia. The patient received ligation of patent ductus arteriosus

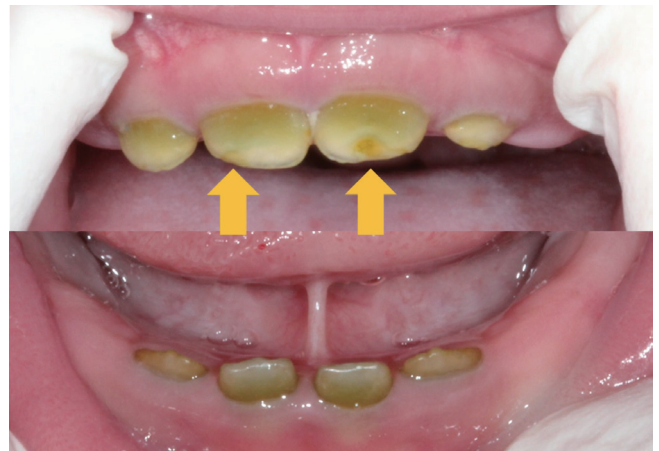

Fig. 3. Green discoloration on the primary upper and lower incisors in a 16-month-old boy. Upper central incisors showed enamel hypoplasia (yellow arrow).

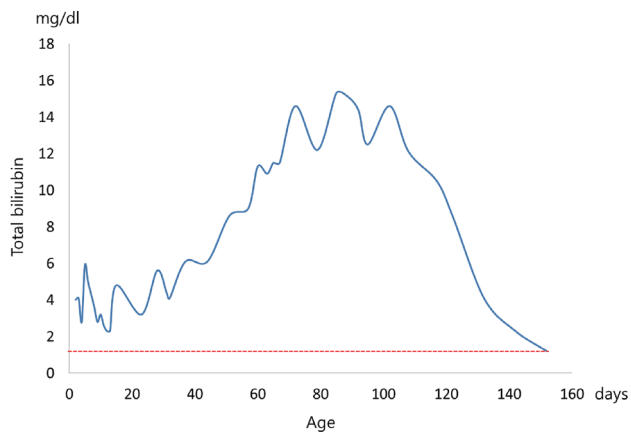


Fig. 4. Total bilirubin levels in the case 2 patient (blue line). Red line is the normal total bilirubin level.

because of an atrial septal defect and patent ductus arteriosus. Similar to case 1, the patient had neonatal hyperbilirubinemia and exchange transfusion histories. The serum bilirubin level peaked at 15.3 mg/dL when he was 84 days old, but had returned to within the normal range at 152 days old (Fig. 4).

III. Discussion

Tooth discoloration may manifest as different colors, with green discoloration being uncommon. Its etiology is classified into extrinsic and intrinsic causative factors. The known extrinsic causes include chromogenic bacteria, systemic antibiotics (e.g., minocycline), copper salts contained in mouth rinse, and copper and nickel metal ions[3,4,14]. Intrinsic causes include hyperbilirubinemia, and drugs such as minocycline and ciprofloxacin[8,15-17]. Tooth discoloration had resulted from intrinsic causes in the present cases, and so it was not physically removed. In addition, they had no history of minocycline or ciprofloxacin administration.

According to Guimaraes and Silva[5], there had been 48 case reports on green teeth up to 2003. The prevalence of green teeth has not been measured officially, but it can be described as rare. The prevalence was similar in women (51.3%) and men (48.7%), with the age at onset most commonly ranging from birth to 11 years, and being more common in primary dentition than permanent dentition.

Hepatobiliary disorders and hematologic disease have been reported as systemic diseases that cause green teeth. The

hematologic diseases include Rh incompatibility, ABO incompatibility disease, hematologic anemia and erythroblastosis fetalis[15,18-21]. Biliary atresia has been reported as the most frequent disease, related to green teeth[5]. Both of the present premature infants were diagnosed as hyperbilirubinemia, which is high likely to cause green teeth, due to immature metabolism in the liver.

There are various phenotypes of tooth discoloration by bilirubin[5]. Green is the most frequently reported, followed by brown, yellow and gray. The degree of discoloration is known to be proportional to the serum bilirubin level[19]; for example, Tank[22] reported that the degree of green discoloration was positively correlated with the jaundice index. On the other hand, it is considered that there is no direct relation between the degree of green discoloration and the duration of hyperbilirubinemia. Marsland and Gerrard[23] reported the green teeth in a patient who had suffered the jaundice for only 1 week, while in the present cases, the jaundice period were 1 week and 5 months.

The primary dentition develops during the prenatal period. Bilirubin accumulates at dental follicles via the blood-stream. The calcification process is initiated at 4 months prenatally and finishes after 11 months. It is known that the primary central incisors form at 1 month and that the primary canine and molars are formed completely at 6 months[24]. In addition, the crown portion with a normal hue that developed when the bilirubin level was normal and the green portion that formed during the hyperbilirubinemia period can be clearly distinguished by lines on the teeth. The color of the tooth returns to normal after the hyperbilirubinemia is treated[18,19], and so it is considered that the degree and location of pigmentation is determined by the timing of hyperbilirubinemia.

Green discoloration of primary teeth was observed in both of the present cases. However, the discoloration portion ranged from the incisal to the middle of the primary central incisor in case 1, while in second case 2 the discoloration started from the middle to cervical portion. This indicates that there was a difference in the times of dental follicle formation when the patients suffered hyperbilirubinemia. In both cases the primary central incisors had enamel hypoplasia, and both patients had an intubation history due to being born prematurely. It has been reported that intubation in the neonatal periods can cause enamel hypoplasia[25], and so it can be considered as a cause of enamel hypoplasia in the maxillary primary central incisor in the present cases.

For aesthetic needs, there are several treatment options, such as tooth bleaching, direct composite restoration and full veneer crown. Full veneer crown is more suitable for restoring extensive discoloration area because of its durability and esthetics[26]. In these cases, patients showed enamel hypoplasia on upper central incisors, so retention of direct composite could be reduced. On the other hand, some adverse effects of tooth bleaching in children and adolescents have been reported. So peroxides in lower concentration are recommended, but bleaching leads to limited clinical satisfaction[27]. In addition, there is a possibility that neonatal hyperbilirubinemia affected tooth development of permanent molars and incisors, so regular check-ups should be performed until eruption.

IV. Summary

2 patients aged a 16 and 22-months visited in the Department of Pediatric Dentistry, Yonsei University Dental Hospital having a chief complaint of erupting teeth with abnormal color. Both patients were diagnosed as green intrinsic discoloration in oral examinations, and they had a systemic history of being born prematurely and suffering neonatal hyperbilirubinemia.

Tooth development is affected by systemic disease that can lead to tooth discoloration. Pediatric dentists may be the first people to observe patients with discoloration in their primary dentition, and they can explain the possibility of systemic disease to their parents. In addition, they should perform regular check-ups to preserve their oral health and resolve the esthetic demands of patients and parents regarding discoloration.

References

1. Lee CH, Lee SD, Kim YJ, *et al.* : Case report of the intrinsic stained teeth of patients with biliary atresia. *J Korean Acad Pediatr Dent*, 31:400-405, 2004.
2. Sulieman M : An overview of tooth discoloration : extrinsic, intrinsic and internalized stains. *Dent Update*, 32:463-464, 466-468, 471, 2005.
3. Tredwin CJ, Scully C, Bagan-Sebastian JV : Drug-induced disorders of teeth. *J Dent Res*, 84:596-602, 2005.
4. Waerhaug M, Gjermo P, Rolla G, Johansen JR : Comparison of the effect of chlorhexidine and CuSO₄ on plaque formation and development of gingivitis. *J Clin Periodontol*, 11:176-180, 1984.
5. Guimaraes LP, Silva TA : Green teeth associated with cholestasis caused by sepsis: a case report and review of the literature. *Oral Surg Oral Med Oral Pathol Oral Radiol Endod*, 95:446-451, 2003.
6. Weerheijm KL: Molar incisor hypomineralization (MIH) : clinical presentation, aetiology and management. *Dent Update*, 31:9-12, 2004.
7. Vennila V, Madhu V, Rajesh R, *et al.* : Tetracycline-induced discoloration of deciduous teeth: case series. *J Int Oral Health*, 6:115-119, 2014.
8. Lumbiganon P, Pengsaa K, Sookpranee T : Ciprofloxacin in neonates and its possible adverse effect on the teeth. *Pediatric Infect Dis J*, 10:619-620, 1991.
9. Watchko JF, Claassen D : Kernicterus in premature infants: current prevalence and relationship to NICHD Phototherapy Study exchange criteria. *Pediatrics*, 93:996-999, 1994.
10. Govaert P, Lequin M, Swarte R, *et al.* : Changes in globus pallidus with (pre)term kernicterus. *Pediatrics*, 112:1256-1263, 2003.
11. Maisels MJ, Watchko JF, Bhutani VK, Stevenson DK : An approach to the management of hyperbilirubinemia in the preterm infant less than 35 weeks of gestation. *J Perinatol*, 32:660-664, 2012.
12. Watanabe K, Shibata T, Kurosawa T, *et al.* : Bilirubin pigmentation of human teeth caused by hyperbilirubinemia. *J Oral Pathol Med*, 28:128-130, 1999.
13. Shibata T, Watanabe K, Oda H, *et al.* : Experimental bilirubin pigmentation of rat dentine and its detection by a qualitative analytical method. *Arch Oral Biol*, 41:509-511, 1996.
14. Dayan D, Heifferman A, Gorski M, Begleiter A : Tooth discoloration--extrinsic and intrinsic factors. *Quintessence Int Dent Dig*, 14:195-199, 1983.
15. Bimstein E, Magliocca K, Cohen D, *et al.* : Hyperbilirubinemic stain: location and extent in dental tissues. *J Clin Pediatr Dent*, 36:75-78, 2011.
16. Auluck A, Thomas M, Kundabala M, Sumanth K : Chlorodontia : Minocycline induced staining of permanent dentition - a case report. *Journal of Conservative Dentistry*, 10: 89-92, 2007.
17. Patil SB, Hugar S, Patil S : Green teeth associated with hyperbilirubinemia: a case report. *Eur J Paediatr Dent*, 15:221-223, 2014.
18. Seow WK, Shepherd RW, Ong TH : Oral changes associated with end-stage liver disease and liver transplantation:

- implications for dental management. *ASDC J Dent Child*, 58:474-480, 1991.
19. Majewski RF, Hess J, Kabani S, Ramanathan G : Dental findings in a patient with biliary atresia. *J Clin Pediatr Dent*, 18: 32-37, 1993.
 20. Naudi AB, Ammari AB, Fung DE : A report of 2 cases of green pigmentation in the primary dentition associated with cholestasis caused by sepsis. *J Dent Child (Chic)*, 75: 91-94, 2008.
 21. Sommer S, Magagnin K, Kramer PF, *et al.* : Green teeth associated with neonatal hyperbilirubinemia caused by biliary atresia: review and case report. *J Clin Pediatr Dent*, 35:199-202, 2010.
 22. Tank G : Two cases of green pigmentation of the deciduous teeth associated with hemolytic disease of the newborn. *J Am Dent Assoc*, 42:302-306, 1951.
 23. Marsland EA GJ : Intrinsic staining of teeth following icterus-gravis. *Br Dent J*, 12:305-310, 1953.
 24. Lunt RC, Law DB : A review of the chronology of eruption of deciduous teeth. *J Am Dent Assoc*, 89:872-879, 1974.
 25. Johnsen D, Krejci C, Hack M, Fanaroff A : Distribution of enamel defects and the association with respiratory distress in very low birthweight infants. *J Dent Res*, 63:59-64, 1984.
 26. Ashima G, Sarabjot KB, Gauba K, Mittal HC : Zirconia crowns for rehabilitation of decayed primary incisors: an esthetic alternative. *J Clin Pediatr Dent*, 39:18-22, 2014.
 27. Lee SS, Zhang W, Lee DH, Li Y : Tooth whitening in children and adolescents: a literature review. *Pediatr Dent*, 27:362-368, 2005.

국문초록

유치열에서의 고빌리루빈혈증과 연관된 초록색 변색

박민경^{1*} · 선예지^{1*} · 강정민¹ · 이효설² · 송제선¹

¹연세대학교 치과대학 소아치과학교실

²경희대학교 치과대학 소아치과학교실

치아 변색을 일으키는 다양한 원인들이 있다. 혈중 빌리루빈의 증가도 치아변색을 일으킬 수 있는데 이는 드문 경우이나, 대부분 초록색 변색이 보고 되었다.

본 증례는 신생아 고빌리루빈혈증 병력이 있는 환아의 유치의 초록색 변색에 대한 것이다. 16개월, 22개월 두 남아가 맹출한 치아의 비정상적인 색을 주소로 내원하였다. 두 환아의 유치는 법랑질저형성증을 수반한 초록색 변색을 보였다. 두 환자 모두 저체중, 조산아였으며, 신생아 고빌리루빈혈증을 진단받았다.

전신적인 질환은 치아의 형성시기에 경조직에 영향을 줄 수 있으며, 변색도 일으킬 수 있다. 정상적인 치아 발육과 환아의 심미적 요구를 충족시키기 위해 정기적인 관찰이 필요하다. 소아치과의사는 유치열기의 변색을 먼저 관찰 할 수 있다. 이와 같은 증례들을 통해 치과의사는 치아변색에 대해 전신적 질환을 추론할 수 있다.

주요어: 초록색, 내인성 변색, 고빌리루빈혈증, 빌리루빈