

## Early Eruption of Maxillary Permanent Canines : Report of 2 Cases

Nakyeong Oh, Jaesik Lee, Soonhyeun Nam, Hyunjung Kim

*Department of Pediatric Dentistry, School of Dentistry, Kyungpook National University*

### Abstract

Congenital absence of the primary canines is very rare. Congenital absence of primary teeth often causes their successors to not develop at all or affects the eruption of their successors. The purpose of this paper was to report the cases of 2 children with early eruption of the maxillary permanent canines at ages 4 and 6 years, respectively, following congenital absence of their maxillary primary canines, which are not common in earlier studies. Although tooth eruption and shedding exhibit some physiological variation, certain clinical cases are extreme. Premature eruption of the maxillary permanent canines may cause complications in terms of the space available for the eruption of adjacent teeth. Additionally, early eruption of permanent teeth increases the need for more careful oral hygiene. Therefore, the pediatric dentist must be alert to such rare cases.

**Key words :** Early eruption, Permanent canine, Congenital absence

### I. Introduction

Congenital absence of teeth occurs frequently in abnormal tooth development. It is caused by failure of growth and of the differentiation of tooth germ[1]. The incidence of congenital absence of primary dentition was  $\leq 0.5\%$  in several studies[2-5]. The incidence of hypodontia ranged from 0.5% among Swedish children to 1.0% among all Caucasians[2]. In a study on tooth agenesis in 193 children with hypodontia of the primary dentition, Dauggard-Jensen *et al.*[6] confirmed that the congenital absence of primary molars, canines, and maxillary primary central incisors was rare.

Localized early eruption of permanent teeth can occur due to early extraction of deciduous teeth[7]. Early eruption of

permanent teeth may also occur due to premature loss of primary teeth, if such loss occurs within 1 year before eruption. However, if the extraction is performed at a very young age, tooth eruption is delayed[8,9].

Ravn[10] showed that primary tooth agenesis was often followed by the agenesis of permanent successors. There is evidence that early loss of primary teeth can affect the eruption of successors, but the precise mechanism underlying the association between congenital absence of primary teeth and eruption of the subsequent permanent teeth is not clear[11,12]. Here, we report 2 rare cases of the early eruption of the permanent canines, combined with congenitally missing primary canines.

---

*Corresponding author : Hyunjung Kim*

*Department of Pediatric Dentistry, School of Dentistry, Kyungpook National University, 2177, Dalgubeol-daero, Jung-gu, Daegu, 41940, Korea*

*Tel: +82-53-600-7201 / Fax: +82-53-426-6608 / E-mail: jungkim@knu.ac.kr*

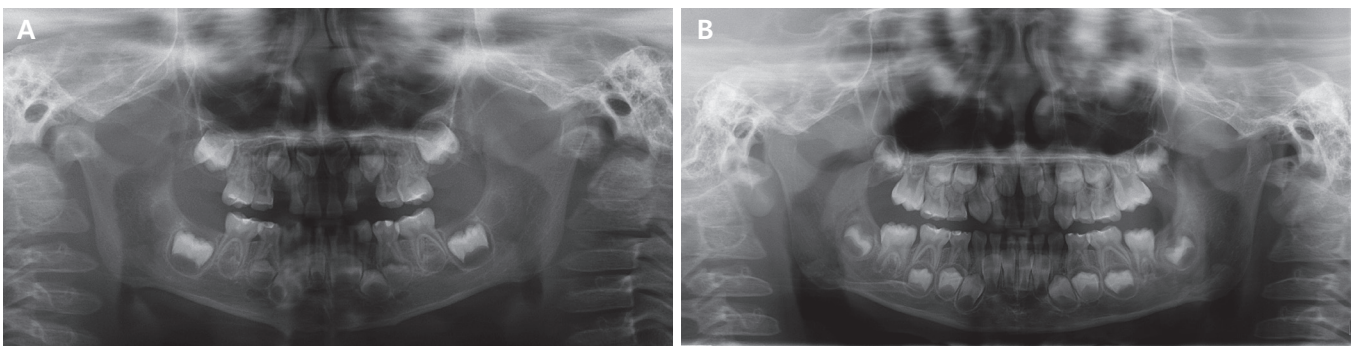
*Received July 25, 2018 / Revised September 14, 2018 / Accepted September 13, 2018*

## II. Case Reports

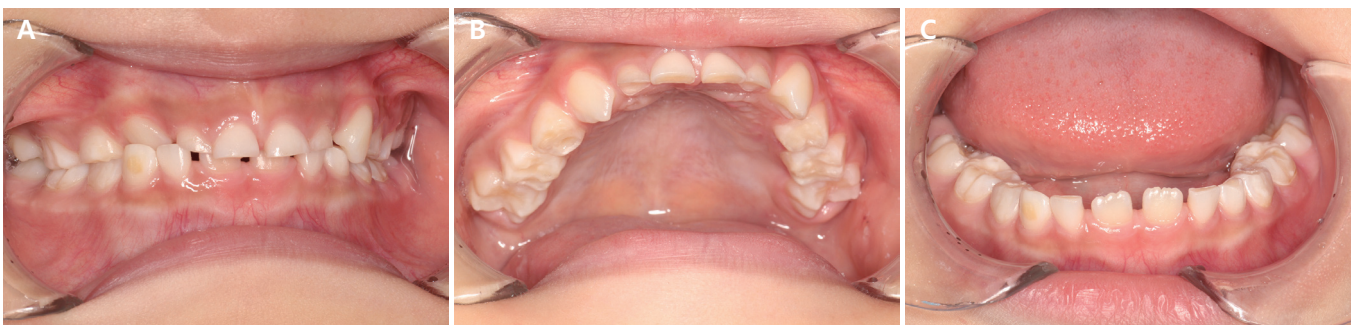### 1. Case 1

A 3-year-old boy presented to the department of pediatric dentistry, Kyungpook national university dental hospital with a chief complaint of a decayed right mandibular primary canine. He was moderately well nourished and had no history of any systemic disease. There was no family history associated with hypodontia. An intra-oral examination and parental history taking revealed congenital absence of both maxillary primary canines. No treatment was needed for the right mandibular primary canine, due to the absence of cavitation and possibility of remineralization. The initial panoramic radiograph revealed that the right and left maxillary canine tooth germs were located below the lateral incisor tooth germs. In terms of the developmental status of the permanent teeth in the anterior space, crown formation was complete to the cemento-enamel junction, and root formation had commenced; spicules were

apparent (Fig. 1A). At the 1-year follow-up, at the age of 4 years, the patient exhibited exposure of the right maxillary permanent canine tip, along with near-complete eruption of the left maxillary permanent canine. At his 3-year follow-up, at the age of 6 years, the crowns of both maxillary permanent canines were completely exposed (Fig. 2). The erupted maxillary canines were yellowish rather than bright blue-white in color, and the crown height was larger than the mesiodistal width. Further intra-oral examination and radiographic analysis showed that the central and lateral incisors had not yet erupted (Fig. 1B, 2). Considering the chronological age, all the teeth other than the maxillary permanent canines were at normal stages of growth (Fig. 1B). After eruption of the maxillary permanent canines, clinical examination revealed a right canine cross-bite (Fig. 2). The patient was scheduled for orthodontic diagnosis associated with a right canine cross-bite when he is old enough to cooperate. Also, periodic follow-up was planned to management of overall oral hygiene and check for development and eruption of adjacent permanent teeth.



**Fig. 1.** Serial panoramic view of the 1st case. (A) The initial panoramic radiograph reveals congenitally missing maxillary primary canine and the permanent canine tooth germ located inferior to the anterior central incisors. (B) At the 3-year follow-up, at the age of 6 years, all of the crowns of both maxillary canines are exposed.

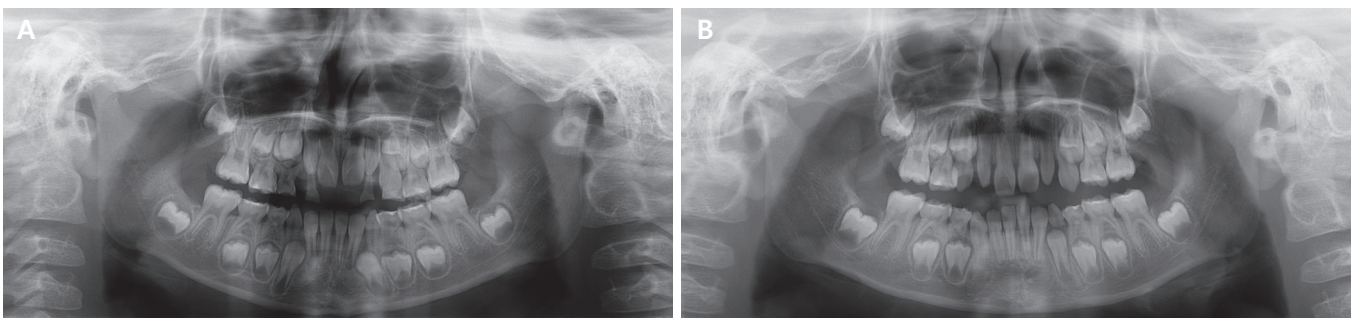


**Fig. 2.** Intraoral view of the 1st case. At the age of 6 years, both maxillary permanent canines are fully erupted and the right permanent canine formed a crossbite with the mandibular primary canine (A-C).

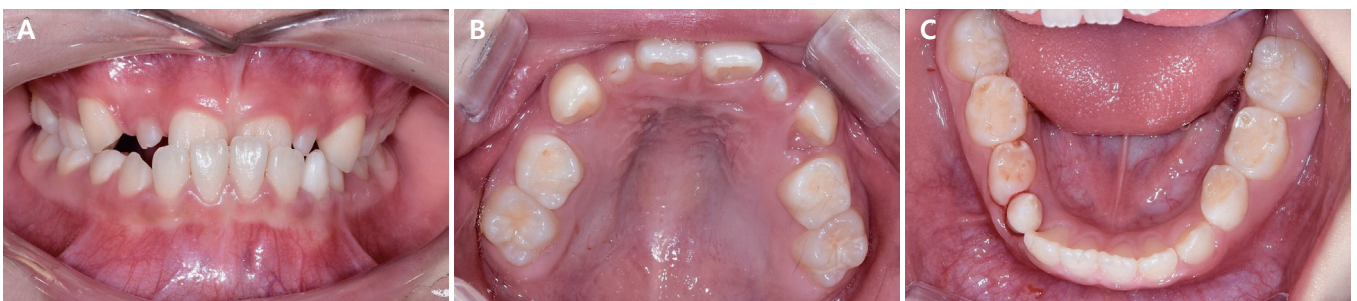## 2. Case 2

A 6-year-old female was referred from a local dental clinic with a chief complaint of early eruption of permanent teeth, with no medical history of any relevant systemic disease. Based on her parental history, we suspected congenital absence of the maxillary primary canines. There was no family history of congenitally missing maxillary canines. Clinical examination revealed mobility of the left maxillary first primary molar, caused by early eruption of the permanent teeth. Anterior crossbite was seen and maxillary lateral incisors were peg-shaped. Based on the clinical and radiographic findings, we diagnosed congenital absence of both maxillary primary canines and early eruption of the left maxillary permanent canine. The initial panoramic radiograph revealed that the root lengths of both maxillary permanent canines were larger than

the crown heights. The root lengths of the maxillary incisors and the lateral incisors were equal to or less than the crown heights (Fig. 3A). We extracted the left maxillary primary molar without local anesthesia, because of mobility and discomfort. When the patient was reviewed 6 months later, the left maxillary permanent canine was fully erupted and a gingival bulge was evident at the right maxillary permanent canine. At the 1-year follow-up, at the age of 7 years, her right permanent canine crown was also fully exposed (Fig. 3B, 4). Intra-oral examination revealed that both maxillary permanent canines were erupted in the first primary molar space. Orthodontic diagnosis was performed due to an anterior cross-bite and an overall lack of space in the maxilla. Orthodontic treatment is scheduled to resolve the anterior cross-bite and space deficiency of the maxilla.



**Fig. 3.** Serial panoramic view of the 2nd case. (A) The panoramic radiograph reveals congenital absence of the maxillary primary canine and the eruption of the maxillary left permanent canine below the left maxillary first primary molar at 6 years of age. (B) At age 7 years, the panoramic radiograph reveals exposure of the maxillary right permanent canine crown and full eruption of the left permanent canine.



**Fig. 4.** Intraoral view of the 2nd case. At her 1-year follow-up check, at the age of 7 years, both maxillary permanent canines are fully erupted (A-C).

### III. Discussion

We report 2 cases exhibiting early eruption (at 4 and 6 years of age) of the upper permanent canines, preceded by congenital absence of the upper primary canines. Earlier studies found that normally developing maxillary permanent canines could erupt at any time between 9.3 and 13.1 years of age[13,14]. Therefore, permanent canine eruption was extremely early in our cases.

The average mesiodistal width of the maxillary primary canine is 6.71 mm in boys and 6.59 mm in girls[14]. Using the same measurement methods, the average mesiodistal width of the maxillary permanent canine is 8.11 mm in boys and 7.79 mm in girls[15]. The recommended measurement method was used in our cases. In the 1st case, the distance between the mesiodistal peaks of the contours of the right and left maxillary permanent canines was 7.85 mm and 8.02 mm, respectively. In the 2nd case, the contour height of the early erupted right and left maxillary permanent canines was 7.62 mm and 7.50 mm, respectively. Additionally, these early erupted canines were yellowish and their crown heights were longer than their mesiodistal widths; these are typical features of maxillary permanent canines.

Hypodontia in the primary dentition is often followed by agenesis of the permanent successor[10,16]. However, the current cases showed clinical and radiographic evidence of maxillary permanent canines. There are many studies related to congenital absence(or hypodontia) and maturation of adjacent teeth in the permanent dentition. According to Ruiz-Mealin *et al.*[17], significant delay in dental age was found in a group with developmental absence of at least 1 primary or permanent tooth. However, another study found no significant difference in the eruption time of teeth in patients with dental agenesis compared to a control group[18]. There are a few studies on the effect of congenitally missing primary teeth on the eruption time of the succeeding permanent teeth. The mechanism of early eruption of the permanent canines in our cases was not clear, so we considered the possible mechanisms based on the features observed in these cases.

Both cases showed congenital absence of the primary canine before early eruption of the maxillary permanent canine. There is controversy about the loss of space when a primary canine is congenitally absent. Shenoy *et al.*[19] reported a case of impacted maxillary permanent canines due to loss of space after congenital absence of primary canine. However, in a case

report by Lee *et al.*[20], there was no loss of space when the maxillary right primary canine was congenitally missing. Loss of space is an important local factor for maxillary canine impaction. As in our first case, preservation of space may influence early eruption of the maxillary permanent canines.

Many genetic factors and signaling molecules are associated with eruption and tooth development[21,22]. Genes such as PAX9, MSX and WNT10A are known to be associated with tooth agenesis and timing of developmental events[23,24]. Considering that early eruption was limited to the maxillary permanent canines and congenital absence of primary canine, the canine developmental genes may have played a role.

The maxillary canines normally develop at a high location in the maxilla, have a long path of eruption, and erupt into the oral cavity after the neighboring teeth[13]. In our 1st case, the panoramic radiograph taken at 3 years of age showed that the permanent canine tooth germ was positioned lower than normal, below the central incisor tooth germ (Fig. 1A). This low location of tooth germ may be a factor in early eruption of permanent canines.

In our cases, root development of the maxillary canine was particularly rapid compared to that of the adjacent teeth. The permanent teeth remain in certain positions within the alveolar bone until the completion of crown development. After the initiation of root development, the teeth then move rapidly toward the occlusal surface[21]. Thus, it is possible that the early eruptions we report are attributable to early root development.

In our 2nd case, the patient's lateral incisors were peg-shaped. It is well established that morphologic anomalies of the maxillary lateral incisors are closely associated with maxillary canine impaction and displacement[25]. Previous studies showed that the presence of smaller-sized lateral incisor roots is an important etiological factor in maxillary canine impaction and displacement[26,27] According to the guidance theory, which suggests that the root of the maxillary lateral incisor plays an important role in inducing normal eruption of the maxillary canine, it is possible to explain that the position of the premature eruption of the maxillary canine was displaced below the first primary molar and the timing of eruption was earlier than normal development[26].

Many reports have described impaction and eruption disorders of the maxillary permanent canines, but early eruption of the maxillary canines is uncommon. Eruption of a permanent mandibular canine in a 5-year-old boy with a congenital absence of the primary canine was reported by Turnbull and

Lai[12]. Similar to our 1st case, the space that would have been occupied by the missing mandibular primary canine was not lost and malocclusion was not observed. Madhu[7] also reported early eruption of a maxillary permanent canine in a 7-year-old girl. However, the primary canine was not congenitally missing.

Eruption disorders may change the eruption sequence, create spatial problems, and, when unilateral, result in occlusion asymmetry[28]. In our 1st case, a cross-bite with the mandibular primary canine was apparent, and both maxillary canines erupted before the maxillary central and lateral incisors, resulting in a lack of anterior space. In our 2nd case, the canine erupted below the maxillary primary first molar, triggering the need for later follow-up and treatment in the context of premolar eruption.

In conclusion, early eruption of maxillary permanent canines against a background of congenitally missing maxillary primary canines is rare. Various explanations are possible, but additional studies are required to define the relevant mechanism. Although this condition is uncommon, patients may experience various complications; their dentists must be careful and knowledgeable.

#### IV. Summary

In this report, 2 cases of early eruption of the maxillary permanent canines, at ages 4 and 6 years, respectively, were described. Both cases had a history of congenitally missing primary canines. Early eruption of the permanent canine is not common, however, when such eruption occurs, it may change the tooth eruption sequence and create spatial problems. Thus, increased attention should be paid to the possibility of early eruption followed by congenital absence of primary teeth.

#### References

1. Craig CE : Abnormalities in number and in the eruption path of the teeth. *Dent Clin North Am*, Jul:435-447, 1968.
2. Carvalho JC, Vinker F, Declerck D : Malocclusion, dental injuries and dental anomalies in the primary dentition of Belgian children. *Int J Paediatr Dent*, 8:137-141, 1998.
3. Magnússon TE : Hypodontia, hyperdontia, and double formation of primary teeth in Iceland. An epidemiological study. *Acta Odontol Scand*, 42:137-139, 1984.
4. Järvinen S, Lehtinen L : Supernumerary and congenitally missing primary teeth in Finnish children. *Acta Odontol Scand*, 39:83-86, 1981.
5. Jeong HK, Yang YM, Kim MA, *et al.* : A clinical study of congenital missing teeth. *J Korean Acad Pediatr Dent*, 36:245-252, 2009.
6. Daugaard-Jensen J, Nodal M, Kjaer I : Pattern of agenesis in the primary dentition: a radiographic study of 193 cases. *Int J Paediatr Dent*, 7:3-7, 1997.
7. Madhu S : Early eruption of permanent canines. *Indian J Dent Res*, 23:428-430, 2012.
8. Posen AL : The effect of premature loss of deciduous molars on premolar eruption. *Angle Orthod*, 35:249-252, 1965.
9. Fanning EA : Effect of extraction of deciduous molars on the formation and eruption of their successors. *Angle Orthod*, 32:44-53, 1962.
10. Ravn JJ : Aplasia, supernumerary teeth and fused teeth in the primary dentition. An epidemiologic study. *Scand J Dent Res*, 79:1-6, 1971.
11. Kerr WJ : The effect of the premature loss of deciduous canines and molars on the eruption of their successors. *Eur J Orthod*, 2:123-128, 1980.
12. Turnbull NR, Lai NN : Eruption of a permanent mandibular canine in a 5-year-old boy. *Int J Paediatr Dent*, 13:117-120, 2003.
13. Ericson S, Kurol J : Longitudinal study and analysis of clinical supervision of maxillary canine eruption. *Community Dent Oral Epidemiol*, 14:172-176, 1986.
14. Baik BJ, Jeon SH, Kim JG, Kim YS : A study of the size of the deciduous teeth. *J Korean Acad Pediatr Dent*, 29:382-388, 2002.
15. Baik BJ, Park JY, Kim JG, Lee DC : A study of the size of the permanent teeth. *J Korean Acad Pediatr Dent*, 30:502-509, 2003.
16. Yang KH, Lim HJ, Choi NK, Kim SM : The prevalence of double teeth and congenital missing teeth in primary dentition and their correlation with the permanent dentition. *J Korean Acad Pediatr Dent*, 34:447-453, 2007.
17. Ruiz-Mealin EV, Parekh S, Gill DS, *et al.* : Radiographic study of delayed tooth development in patients with dental agenesis. *Am J Orthod Dentofacial Orthop*, 141:307-314, 2012.
18. Ben-Bassat Y, Babadzhanov D, Aizenbud D, *et al.* : Maturation of teeth adjacent to dental agenesis site. *Acta Odontol Scand*, 72:516-522, 2014.

19. Shenoy M, Yogech TL, Shivkumar MS : Congenitally missing maxillary primary canines with impacted successors. *Oral Maxillofac Pathol J*, 6:643-645, 2015.
20. Lee JE, Lee JH, Choi BJ, *et al.* : The space of congenitally missing of primary canine with odontoma. *J Korean Acad Pediatr Dent*, 37:233-239, 2010.
21. Nanci A : Ten Cate's Oral Histology, 8th ed. Mosby, 233-236, 2013.
22. Kim HM, Yang SD, Nam SH, *et al.* : Relationship between the developmental stage and chronological age, and the changes of tooth position in relation to tooth development in mandibular permanent teeth. *J Korean Acad Pediatr Dent*, 29:607-617, 2002.
23. Cobourne MT : Familial human hypodontia-is it all in the genes? *Br Dent*, 203:203-208, 2007.
24. Park MK, Shin MK, Song JS, *et al.* : Prevalence of delayed tooth development and its relation to tooth agenesis in Korean children. *Arch Oral Biol*, 73:243-247, 2017.
25. Becker A, Smith P, Behar R : The incidence of anomalous maxillary lateral incisors in relation to palatally-displaced cuspids. *Angle Orthod*, 51:24-29, 1981.
26. Kim Y, Hyun HK, Jang KT : Morphological relationship analysis of impacted maxillary canines and the adjacent teeth on 3-dimensional reconstructed CT images. *Angle Orthod*, 87:590-597, 2017.
27. Chaushu S, Sharabi S, Becker A : Tooth size in dentitions with buccal canine ectopia. *Eur J Orthod*, 25:485-491, 2003.
28. Koo HJ, Lee JC, Hahn SH : Premature eruption of permanent successors: A case report. *J Korean Acad Pediatr Dent*, 26:232-239, 1999.

국문초록

## 상악 영구 견치의 조기 맹출 : 증례보고

오나경 전공의 · 이제식 전문의 · 남순현 교수 · 김현정 교수

*경북대학교 치의학대학원 소아치과학교실*

유치의 선천적 결손은 흔하지 않으며, 특히 유견치의 선천적 결손은 드물다. 일반적으로 선천적 결손에 따른 후속 영구치에 미치는 영향으로 후속 영구치 또한 선천적 결손 되거나, 발육 시기에 영향을 주는 경우가 보고되어졌다. 본 증례는 상악 유견치의 선천적 결손을 지닌 2명의 환아에게서 각각 4세, 6세경 영구 견치가 조기 맹출 된 증례가 있어 보고하였다. 이러한 조기 맹출이 일반적이지 않더라도, 발생 시에 환자는 공간과 관련된 문제가 발생할 수 있으며 좀 더 주의 깊은 구강위생 관리가 필요하다. 이에 본 증례를 통하여 유견치 선천적 결손 후 후속 영구치의 조기 맹출 가능성에 대하여 보고하는 바이며, 조기맹출 시 발생할 수 있는 문제점과 관련하여 임상가들은 주의 깊은 관찰이 필요하다.