

Post-endodontic Restoration on Erupting Permanent First Molars Using Endocrown with a Polyglass Composite Resin: Report of Two Cases

Hyuntae Jeong, Seonmi Kim, Jaehwan Kim, Namki Choi

Department of Pediatric Dentistry, School of Dentistry, Chonnam National University

Abstract

Post-endodontic restorations are both important and challenging for clinical success in endodontically treated posterior teeth. Several options have been proposed to restore endodontically treated molars.

In pediatric dentistry, restoration using conventional single crowns, especially for partially erupted molars with insufficient retentive tooth structure, has proven to be difficult. However, the endocrown presents a conservative and esthetic restorative alternative to conventional crowns with post-and-core, as it acquires additional retention within the pulp chamber. The tooth preparation consists of a circular, equigingival, butt-joint margin and a central retention cavity in the pulp chamber that helps to construct both the crown and core as a single unit.

This case report describes the esthetic and conservative endocrown restorations of erupting permanent first molars with extensive coronal destruction.

Key words : Endocrown restoration, Post-endodontic restoration, Extensive coronal destruction, Partially erupted molar

I . Introduction

A final restoration after endodontic treatment is necessary in order to preserve and protect the remaining tooth structure, while restoring adequate esthetics and function. Several options are available and the choice depends on the structural integrity of the tooth, esthetics, and protective requirements[1].

In permanent molars in the partially erupting stage of children and adolescents, the restoration of endodontically treated teeth with extensive coronal destruction due to caries, failure of restorations, or a developmental dental anomaly has been

a challenge for all dentists. Due to reduced coronal structure and lack of adequate interocclusal space for the restoration, these teeth have compromised biomechanical principles of retention and resistance[2].

One treatment option is fabrication of an intracanal post-and-core, followed by a full-coverage crown to reinforce the restoration retention. Although this intracanal post supports the coronal structure, there are still some risks of root perforation; moreover, over-preparation can cause stress in the already weakened root canal walls[3].

Another viable restorative option is the use of preformed

Co-corresponding author : Jaehwan Kim

*Department of Pediatric Dentistry, School of Dentistry, Chonnam National University, 33 Yongbong-ro, Buk-gu, Gwangju, 61186, Korea
Tel: +82-62-530-5660 / Fax: +82-62-530-5669 / E-mail: jhkim79@jnu.ac.kr*

Co-corresponding author : Namki Choi

*Department of Pediatric Dentistry, School of Dentistry, Chonnam National University, 33 Yongbong-ro, Buk-gu, Gwangju, 61186, Korea
Tel: +82-62-530-5660 / Fax: +82-62-530-5669 / E-mail: nkchoi@jnu.ac.kr*

Received August 27, 2018 / Revised October 19, 2018 / Accepted October 15, 2018

metal crowns (PMCs) or stainless steel crowns. These are mainly used in the deciduous teeth after pulp therapy. In permanent teeth, the PMCs could be used successfully as an interim restoration in a broken-down or traumatized tooth until the permanent restoration can be carried out. And they could be used as the restoration in a permanent molar that requires full coverage but is still partially erupted[4]. Despite the wide acceptance of PMCs on permanent molars, there have been concerns raised regarding their lack of accurate cervical fit and the after-effect on periodontal tissues, lack of esthetics, difficulties in tooth preparation, and adjustment of the PMCs[5].

Therefore, more conservative, esthetic, and functional alternatives are needed. As adhesive dentistry has remarkably developed over the last several decades, there are various resin adhesives with high bond strength and thin film thickness. The development of these materials has led to the availability of high-strength restorative materials that are capable of being etched and then luted with adhesives for better retention. Endocrown is a recently introduced indirect restorative technique that has gained clinical popularity for restoration of endodontically treated posterior teeth. Endocrown is formed from a monoblock containing the coronal portion integrated into the apical projection that fills the pulp chamber space, and possibly the root canal entrances.

The purpose of this case report is to discuss the use of the endocrown in pediatric dentistry to replace single crowns with intraradicular retention or PMCs. Here, we present two clinical case reports on endocrown restorations performed in partially erupted mandibular and maxillary first molars with extensive coronal destruction due to dental caries.

II. Case Report

1. Case I

A 9-year-old male patient, with delayed development and mental retardation, visited the clinic for the disabled in Chonnam National University Dental Hospital with a chief complaint of multiple caries. The intraoral examination revealed that multiple teeth were affected by caries, especially, the left mandibular first molar with extensively destructed coronal structure (Fig. 1A). On radiographic examination, a periapical lesion was detected, indicating the need for endodontic treatment (Fig. 1B). The coronal height of the remainder crown of the tooth was less than 3 mm.

Under general anesthesia, multiple restorations with composite resin were done to restore the decayed teeth and root canal treatment was performed on the left mandibular first molar. Due to the insufficient interocclusal space, post-endodontic restoration was planned with a conservative approach using endocrown fabricated with the ceramic-filled polyglass composite resin, Artglass® (Heraeus Kulzer GmbH, Hanau, Germany).

For following appointments, intramuscular injection of midazolam in conjunction with nitrous oxide was performed to induce conscious sedation. Before the preparation for the endocrown, the shade selection was done and the floor of the pulpal chamber was flattened with a flowable resin (Luxacore Z, DMG, Hamburg, Germany). The preparation was initiated and its margin was almost an equigingival or partially subgingival butt joint. An apical projection cavity into the entire pulp chamber was made for a single unit restoration comprising of the crown and the core. The interocclusal space and the entire cavity were evaluated (Fig. 2). An impression was taken with polyvinyl siloxane light and mono body impression materials

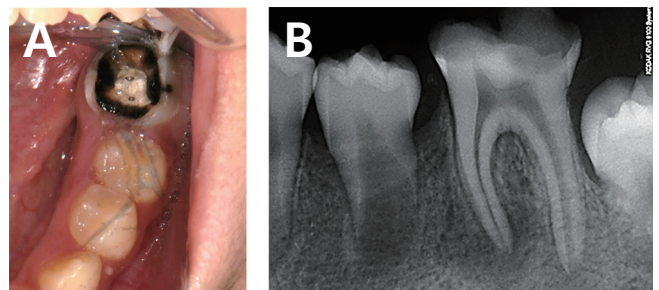


Fig. 1. (A) Clinical aspect of the left mandibular first molar in a 9-year-old male patient shows extensive loss of coronal dental tissue, (B) Initial radiographic aspect shows the cavity nearing the pulp.

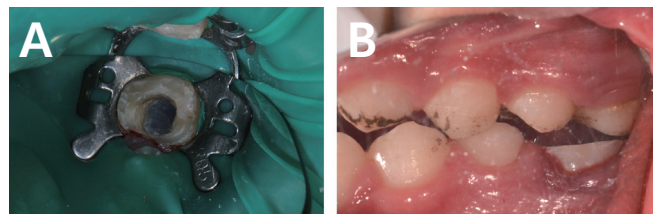


Fig. 2. (A) The tooth preparation for the endocrown restoration, (B) Occlusal clearance is evaluated, with the circumferential butt joint margin visible.

(Honigum, DMG, Hamburg, Germany) using a retraction cord. A provisional restoration was constructed with a light-cure elastic material (Temp-it, SPIDENT Co., Ltd., Incheon, Korea).

The endocrown was fabricated with a polyglass composite resin, Artglass®, in the laboratory (Fig. 3). The try-in of the finished endocrown was followed by checking of the proximal contacts with the surrounding teeth and the marginal fit on the prepared tooth. The internal adhesive surfaces were abraded with 50 μm aluminum oxide airborne-particles at 2 bar for 2 seconds. The tooth surface was etched with 37% phosphoric acid (ETCH-37, BISCO, Illinois, USA) for 20 seconds, rinsed with running water, and dried with oil-free air. The dentin adhesive (All-bond Universal, BISCO, Illinois, USA) was applied and light-cured for 20 seconds. A dual curable resin luting cement (Rely X U200, 3M ESPE, Seefeld, Germany) was then applied on the internal surface of the endocrown. The endocrown was placed on the prepared tooth, and a light pressure was applied with a ball burnisher over the center of the restoration to spread the cement uniformly (Fig. 4A). Light curing was done over the margin, and excessive resin cement was removed. It was

then examined carefully for occlusal interference and finished with the composite finishing and polishing system (Enhance, Dentsply Caulk, Milford, DE, USA).

The final restoration is shown in the figures below (Fig. 4B, 4C). The clinical and radiographic evaluation revealed no secondary caries, fracture, or defect of the endocrown after a 2-year follow-up (Fig. 5).

2. Case II

A 9-year-old female patient visited the department of pediatric dentistry at Chonnam National University Dental Hospital with a chief complaint of pain in the left maxillary first molar. A clinical examination showed a pulp polyp resulting from extensive carious exposure. Based on the clinical and radiographic findings, the maxillary left first molar was diagnosed with chronic hyperplastic pulpitis (Fig. 6), and the root canal treatment was performed. Considering the amount of remaining tooth structure and the partially erupting stage of the tooth, the endocrown was selected as the post-endodontic

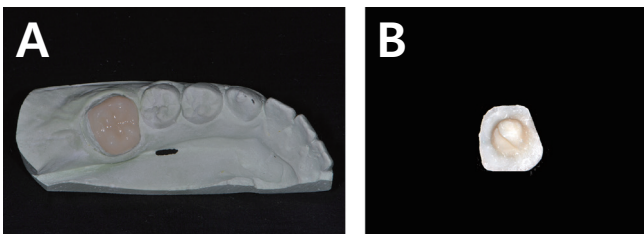


Fig. 3. Endocrown restoration. (A) The endocrown fabricated with ceramic-filled polyglass composite resin in a laboratory, (B) The retentive apical projection for the entire pulp chamber is visible.

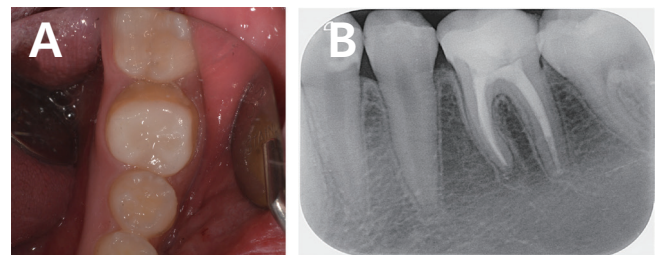


Fig. 5. (A) Occlusal view of a clinical follow-up after 2 years, (B) Radiographic image after a 2-year follow-up.

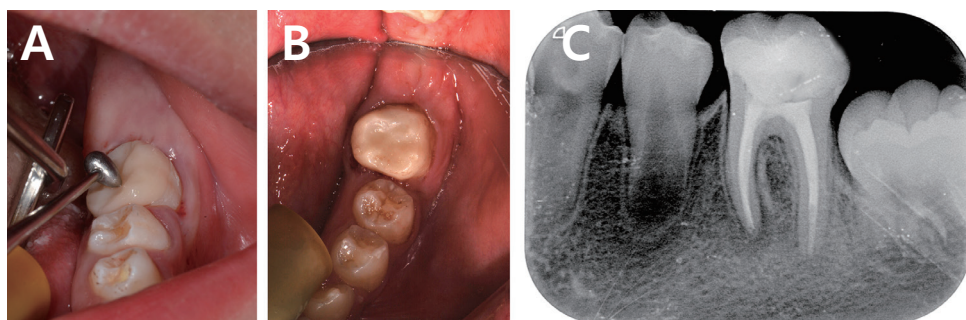


Fig. 4. (A) Conventional adhesive system is used to bond the endocrown to the prepared tooth, (B) Occlusal view after final cementation, (C) Radiographic image after cementation and polishing.

restoration along with an additional request for esthetics by the patient.

The tooth preparation and the impression for endocrown were performed after the shade selection, in a similar way as described in the previous case. The Artglass® composite resin was used for the fabrication of the endocrown in the laboratory. After a try-in, the endocrown was cemented using a dual curable resin luting cement (Fig. 7). Clinical and radiographic evaluation of a 2-year follow-up showed no secondary caries, fracture, or defect of the tooth (Fig. 8).

III. Discussion

Modern clinical concepts to restore endodontically treated posterior teeth are based on the principles of the minimal invasive dentistry[1]. Preservation of the remaining tooth structure is critical to build the foundation for a post-endodontic restoration for strengthening the restored tooth. Other important considerations in the restoration of endodontically treated teeth are the interocclusal space and the height of the remaining coronal tissue, which influences the strength and retention

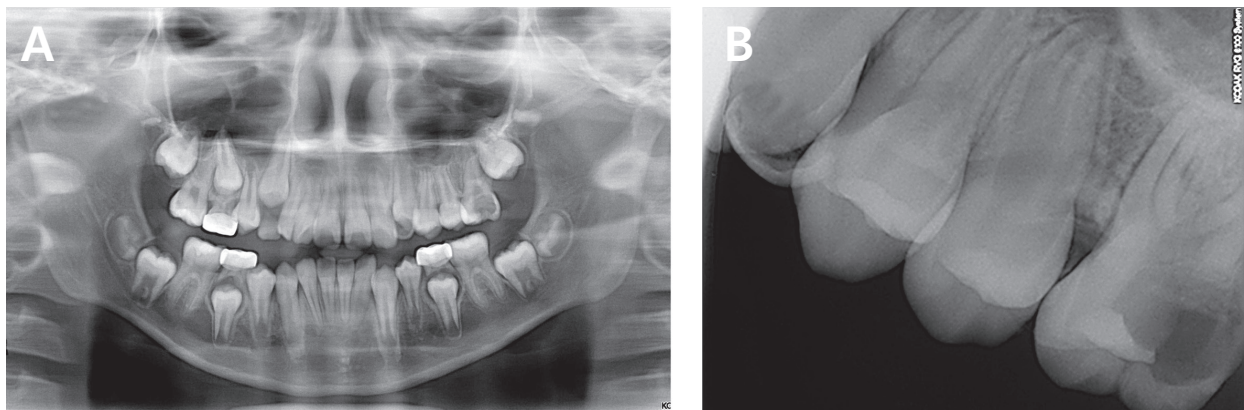


Fig. 6. (A) Initial panoramic radiograph of the left maxillary first molar (#26) in a 9-year-old female patient, (B) Periapical radiograph of the tooth, #26, with severe loss of distal coronal tissue.

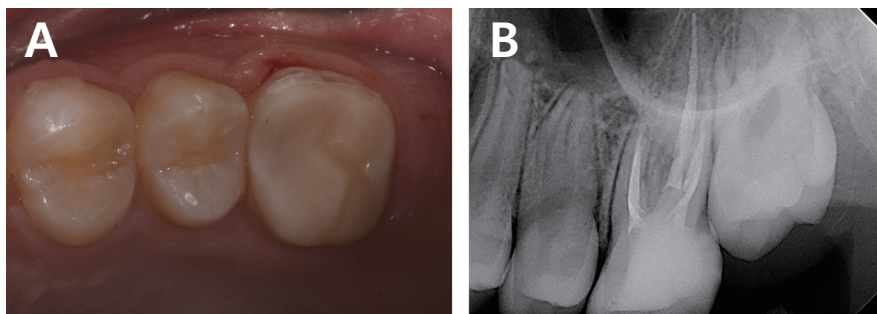


Fig. 7. (A) Occlusal view, (B) Radiographic aspect after cementation of endocrown.

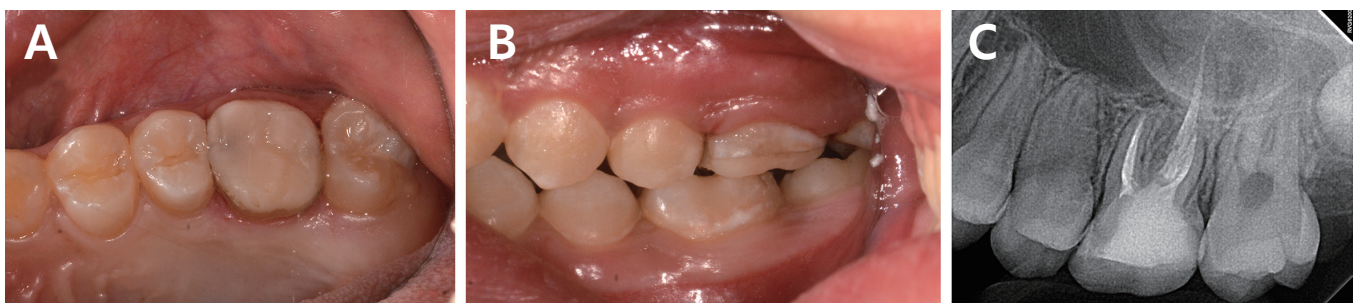

Fig. 8. (A) Occlusal view, (B) Buccal view, (C) Radiographic image after a 2-year follow-up.

of the final restoration[4,5]. Especially in pediatric dentistry, partially erupted molars with extensive coronal destruction or less coronal height have an insufficient crown height to gain retention for the full crown cast restoration. Endocrown appears to be a suitable option for restoring the endodontically treated teeth in the situations stated above.

With the development of the adhesive cementation system, the necessity of macro-retentive preparation for conventional post-and-core and full cast crowns has decreased[6]. Other restoration options such as inlay, onlay, overlay, Sharonlay, and Richmond crown have been introduced for the teeth with extensive loss of the coronal structure after endodontic treatment and follow the concept of conservative preparation and supragingival level finish[1]. Richmond crown and Sharonlay were introduced many years ago with the idea of developing a single unit restoration. As the conservative and esthetic addition to this continuum, a new type of adhesive endodontic restoration was introduced[7]. The first study published was conducted by Pissis[7] in 1995, which described the monoblock porcelain technique on teeth with extensive loss of coronal structure. It was Bindl and Mörmann[8] who named this restorative procedure "endocrown" in 1999 as adhesive endodontic crowns, and characterized as a total porcelain crown fixed to endodontically treated posterior teeth.

Endocrowns are indicated for molars in the following conditions: those with excessive loss of coronal dental tissue due to caries or recently increasing molar incisor hypomineralization; limited interocclusal space due to clinically reduced crown height as seen in partially erupted molars of the mixed dentition stage; roots that are too short, obliterated, dilacerated, or fragile for conventional post and crown; or favorable pulp chamber retention cavity[9]. Meanwhile, contraindications of the endocrown include evidential increase in functional and lateral stresses as with steep occlusal anatomy, wear facets, or parafunctional habits; in cases where adhesion cannot be assured; pulp chambers less than 3 mm in depth; or cervical margins less than 2 mm in width for most of the circumference[1]. In such cases, full-coverage crowns, with or without post, could be the alternative. Although endocrowns are desirable for all teeth, they should be restricted to the restoration of posterior teeth, especially molars. Bindl *et al.*[10] observed in the previous study that the endocrowns with premolars were more likely to fail than with the molars. This could possibly be because the premolars have a smaller dental structure area in the pulp chamber and consequently a smaller adhesive

surface. Additionally, the configuration of premolars, where the height is greater than the width, could create a long lever arm and hence, increase the risk of adhesive rupture and displacement[11].

Endocrowns have several advantages over conventional full-coverage crowns. They are easier to handle, less complex, more practical, less expensive, and less time-consuming[2]. Conventional intracanal posts with intraradicular retentive supports for coronal restoration can generate a wedge effect on the root and have a longer laboratory time[12]. Moreover, in the case of failure, the invasive procedure could lead to the larger loss of tooth structure, making it difficult to re-intervene[13]. In the previous studies, the endocrown restorations presented greater fracture strength than indirect conventional crowns retained with glass fiber posts and resin composite cores[14,15]. Mörmann *et al.*[16] showed that the fracture resistance of endocrowns with an occlusal thickness of 5.5 mm was two times higher than that of ceramic crowns with a classic preparation and an occlusal thickness of 1.5 mm. The design of preparation is conservative and involves the minimal biological width compared to the conventional crowns[3,17]. Additionally, the normal enamel is still retained after the cavity preparation, which improves the durability of the adhesive system. The bonding surface offered by the pulpal chamber of the endocrown is often equal or even superior to that obtained from the bonding of a radicular post of 8 mm depth[1,18,19]. However, endocrowns have disadvantage in debonding and there is a possibility of root fracture because of the difference in the modulus of elasticity between the hard restoration and soft dentin[11].

The preparation for the endocrown includes an occlusal reduction to achieve the height of the occlusal space of at least 2 mm in the axial direction. The supragingival or equigingival circumferential butt-joint margin is approximately 1.0 to 2.0 mm in width, with an axial preparation to make a central retention cavity inside the pulp chamber that eliminates undercuts in the access cavity[7,8]. This design makes both the crown and core a single unit monoblock structure; thus, the root canal preparation can be omitted. The suggested dimensions of the retention cavity are 5 mm diameter and 5 mm depth in molars, but the precise dimensions are not clearly determined[15]. Sometimes, it could be necessary to apply the composite resin on the pulp chamber walls or floor to block the undercuts (Fig. 9). This suits the restorative needs as described in this case report, thereby further conserving sound

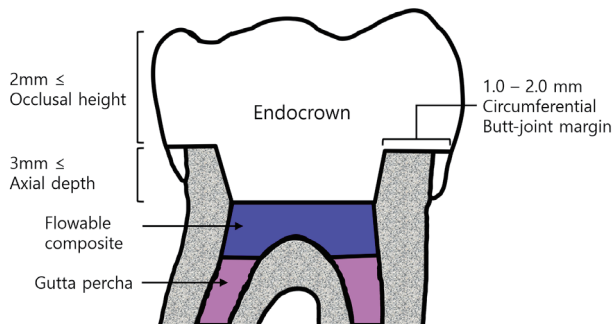


Fig. 9. Schematic drawing of the tooth preparation for the endocrown restoration. Flowable composite resin could be applied for blocking undercuts.

tooth structure.

Endocrowns constructed with CEREC system (Sirona, Bensheim, Germany) using CAD/CAM (computer aided design/manufacturing) were first introduced by Bindl and Mörmann[8]. Recently, other systems and materials have been employed. The pressable ceramics like Emax and Empress as well as CAD/CAM ceramics have reduced the brittleness of ceramic and increased clinical performance in various applications[1,6]. However, the use of composite materials to fabricate endocrown has also increased in recent years due to the development of composite resin and the highly strengthened indirect composites. In this case report, the endocrowns were fabricated with the ceramic-filled polyglass composite resin, Artglass®. Resin composite materials are as esthetic as the ceramic crowns, and their level of fracture resistance is clinically acceptable. Composite resin endocrowns are easy to use and less expensive as compared to those fabricated with ceramic. They can also be repaired after being fractured due to functional use[20]. Ohlmann *et al.*[20] showed that the preparation for the composite resin crowns could be more conservative in comparison to that of ceramic crowns. Because a high-strength reinforcing core was not necessary, thereby it made minimal occlusal reduction possible. However, their tendency to accumulate plaque, necessity for polishing, and wear of strength in function under shear occlusal stresses was clinically unfavorable.

The bonding material constitutes the critical interface between the restoration material and the prepared tooth. The single bond interface enhances cohesion[7,11]. In addition to the adhesive properties, its modulus of elasticity is important because it should be able to absorb the pressure[10]. It has

been reported that certain types of adhesive agents affect fracture resistance, which was higher in crowns cemented with resin cement than crowns luted with glass ionomer cement[20]. Therefore, endocrowns in the cases described above were luted with a dual curable resin adhesive.

In this clinical case report, it was decided that the endocrown restoration would be appropriate for partially erupting molars with extensive loss of coronal structure after endodontic treatment. The restorations were fabricated with Artglass®, and the prognosis was good during the 2-year follow-up.

IV. Summary

If the case is carefully selected, the endocrown offers some advantages in the restoration of endodontically treated molars. It promotes adequate function and favorable esthetics, as well as the biomechanical integrity of the compromised structure of non-vital posterior teeth by dispensing the use of a post-and-core filling.

In the field of pediatric dentistry, endocrowns could be used as a permanent alternative to conventional full crown with post-and-core, or as a transient interim restoration on permanent molars during continuing tooth eruption in the mixed or early permanent dentition of children and adolescents.

In these clinical cases, the 2-year survival of the endocrown restorations could be considered a success.

References

1. Carlos RB, Thomas Nainan M, Rose R, *et al.* : Restoration of endodontically treated molars using all ceramic endocrowns. *Case Rep Dent*, 2013:210763, 2013.
2. Randall RC : Preformed metal crowns for primary and permanent molar teeth: review of the literature. *Pediatr Dent*, 24:489-500, 2002.
3. Koleventi A, Sakellari D, Arapostathis KN, Kotsanos N : Periodontal impact of preformed metal crowns on permanent molars of children and adolescents: a pilot study. *Pediatr Dent*, 40:117-121, 2018.
4. Ploumaki A, Bilkhair A, Strub JR, *et al.* : Success rates of prosthetic restorations on endodontically treated teeth; a systematic review after 6 years. *J Oral Rehabil*, 40:618-630, 2013.
5. Dietschi D, Duc O, Krejci I, Sadan A : Biomechanical considerations for the restoration of endodontically treated teeth:

- a systematic review of the literature, Part II (Evaluation of fatigue behavior, interfaces, and in vivo studies). *Quintessence Int*, 39:117-129, 2008.
6. Lander E, Dietschi D : Endocrowns: a clinical report. *Quintessence Int*, 39:99-106, 2008.
 7. Pissis P : Fabrication of a metal-free ceramic restoration utilizing the monobloc technique. *Pract Periodontics Aesthet Dent*, 7:83-94, 1995.
 8. Bindl A, Mörmann WH : Clinical evaluation of adhesively placed Cerec endo-crowns after 2 years-preliminary results. *J Adhes Dent*, 1:255-265, 1999.
 9. Rocca GT, Krejci I : Crown and post-free adhesive restorations for endodontically treated posterior teeth: from direct composite to endocrowns. *Eur J Esthet Dent*, 8:156-179, 2013.
 10. Bindl A, Richter B, Mörmann WH : Survival of ceramic computer-aided design/manufacturing crowns bonded to preparations with reduced macroretention geometry. *Int J Prosthodont*, 18:219-224, 2005.
 11. Valentina V, Aleksandar T, Dejan L, Vojkan L : Restoring endodontically treated teeth with all-ceramic endocrowns - case report. *Serbian Dent J*, 55:54-64, 2008.
 12. Sorensen JA, Engleman MJ : Effect of post adaptation on fracture resistance of endodontically treated teeth. *J Prosthet Dent*, 64:419-424, 1990.
 13. Bergman B, Lundquist P, Sjögren U, Sundquist G : Restorative and endodontic results after treatment with cast post and cores. *J Prosthet Dent*, 61:10-15, 1989.
 14. Biacchi GR, Basting RT : Comparison of fracture strength of endocrowns and glass fiber post-retained conventional crowns. *Oper Dent*, 37:130-136, 2012.
 15. Chang C, Kuo J, Lin Y, Chang Y : Fracture resistance and failure modes of CEREC endo-crowns and conventional post an core-supported CEREC crowns. *J Dent Sci*, 4:110-117, 2009.
 16. Mörmann WH, Bindl A, Lüthy H, Rathke A : Effects of preparation and luting system on all-ceramic computer-generated crowns. *Int J Prosthodont*, 11:333-339, 1998.
 17. Cohen S, Hargreaves KM : Pathways of the pulp, 10th ed. Elsevier Mosby, 2011.
 18. De Munck J, Van Landuyt K, Van Meerbeek B, *et al.* : A critical review of the durability of adhesion to tooth tissue: methods and results. *J Dent Res*, 84:118-132, 2005.
 19. Peumans M, Kanumilli P, Van Meerbeek B, *et al.* : Clinical effectiveness of contemporary adhesives: a systematic review of current clinical trials. *Dent Mater*, 21:864-881, 2005.
 20. Ohlmann B, Gruber R, Eickemeyer G, Rammelsberg P : Optimizing preparation design for metal-free composite resin crowns. *J Prosthet Dent*, 100:211-219, 2008.

국문초록

맹출 중인 제1대구치의 근관 치료 후 엔도크라운을 통한 수복 증례 보고

정현태 · 김선미 · 김재환 · 최남기

전남대학교 치의학전문대학원 소아치과학교실

구치 근관 치료의 임상적 성공은 근관 치료 후 수복에 의해 결정된다. 다양한 방법들이 근관 치료된 구치를 수복하기 위해 제안되고 있다.

소아청소년치과학 영역에서 근관 치료가 필요한 맹출 진행 중인 영구 구치의 전통적인 포스트 코어 및 전장관 수복은 어려움이 많고 과도한 치질 삭제를 유발한다. 치수강을 통한 적절한 유지력이 제공된다면 엔도크라운(Endocrown)은 보존적이고 심미적인 대안이 될 수 있다. 치아 형성은 크라운-코어 일체형의 수복물을 구성하기 위해 치은연과 같은 높이의 버트 조인트(butt-joint) 변연과 치수강 내부 전체의 유지 와동으로 이루어진다.

이 증례 보고는 광범위하게 손상된 부분 맹출된 제1대구치의 엔도크라운을 통한 심미적이고 보존적인 수복의 결과를 기술하고 있다.