

: 1


Triple Anal Fistulas: Report of a Case

In-Geun Seo, M.D.

Usually a patient has an anal fistula, which has an internal (primary) opening, an external (secondary) opening, and a tract connecting the two. Uncommonly, the external openings are more than one but mostly lead to a single internal opening. Rarely the multiple external openings lead to more than one internal opening. Each internal opening, its corresponding tract(s), and its external opening(s) are considered as a separate (independent) fistula. The patient in question had three external openings leading to three separate internal openings. When multiple external openings are present, injection of a dye or hydrogen peroxide to identify the internal openings must be considered. (*J Korean Surg Soc* 2003;64:266-268)

Key Words: Anal fistula, Multiple, Independent, Internal opening

Haruhakmun Surgical Clinic, Seoul, Korea



(induration) . Hb 11.8 g/dl, WBC 10400/ul, WBC differential count (Stab Neutro 0%, Segmented Neutro 65%, Lymphocyte 27%, Monocyte 7%, Eosinophil 1%, Basophil 0%), Platelet 238 /ul, Prothrombin Time 12 sec, Actevated PTT 32.5 sec, Urinalysis: negative, Blood Glucose 136 mg/dl, Total cholesterol 197 mg/dl, Creatinine 0.9 mg/dl, r-GTP 28 IU/L, S-GOT 13 IU/L, S-GPT 10 IU/L, Alk. Phosphatase 104 IU/L, Albumin 4.2 g/dl, CPK 86 IU/L, Sodium 136 mEq/L, Potassium 4.5 mEq/L, VDRL Non-reactive, HIV Ab Negative . S

2, 6, 8 (Fig. 2).

(probe)

Parks(I) (uncomplicated transsphincteric type) Fig. 3

0.5% lidocaine in 1 : 200,000 epinephrine

: 569-70

ⓞ 142-074,

Tel: 02-993-8528, Fax: 02-993-8529

E-mail: seoingeun@hanmail.net

: 2002 9 30 , : 2002 11 5

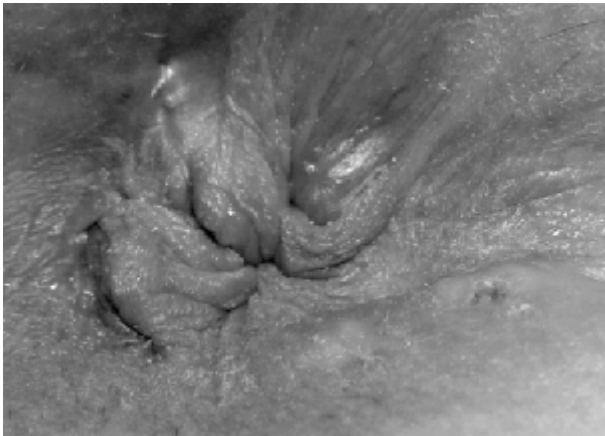

Fig. 1. Preoperative photograph of the perineum with patient in right lateral position, showing three external openings of fistulas. There is a opening appearing as a dimple in the left anterolateral segment of the perineum, There is a opening, which looks like a pimple, in right posterolateral segment. And there is a opening with small amount of yellowish discharge in the right posterior segment near posterior midline. There are hemorrhoids with external components in the left posterior, right anterior, and right posterior.

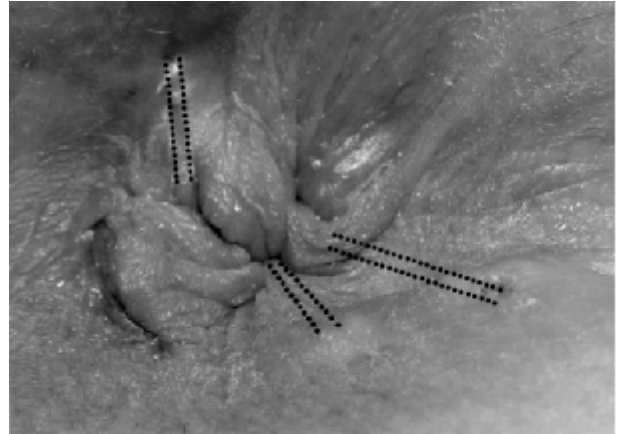

Fig. 3. A photograph of the perineum with patient in right lateral position, showing three independent fistulas, indicated by double dotted lines. During operation, the three internal openings were found at 2 o'clock, 6 o'clock and 8 o'clock.

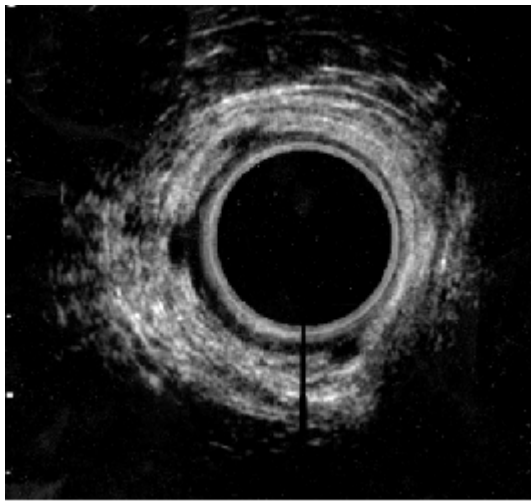


Fig. 2. Preoperative anal ultrasound with patient in left lateral position, suggesting the three sites of the internal openings. There are three hypoechoic areas in the hyperechoic zone of longitudinal muscle and external sphincter at 2 o'clock, 6 o'clock and 8 o'clock.

(circumcision)

가

(the cored out tunnel)

(coring out).

polyglycolic acid sutures

(Dexon, Davis+Geck, USA)

(8), (6 30)

5 20 follow-up

가 . 2

. Mirelman Corman(2) 2 2 가

2 . Mazier(3) 1000

(multiple anal fistulas) 2.3% , 22

2 , 1 3

. Hill(4) 626

4.3% , 24 2 가

, 2 3 가 , 1 4

가 . Chulani Kulkarni(5) 5

가 1 4 가

1 . 가 ,

(multiple anal fistulas)

(internal opening) , (primary tract) 2

가 ,
 가
 가
 가

REFERENCES

1) Parks AG, Gordon PH, Hardcastle JD. A classification of

fistula-in-ano. *Br J Surg* 1976;63:1-12
 2) Mirelman D, Corman ML. Dual anal fistulas-an uncommon manifestation of Fistula-in-ano: report of two cases. *Cis Colon Rectum* 1978;21:54-5.
 3) Mazier WP. The treatment and care of anal fistulas: a study of 1,000 patients. *Dis Colon Rectum* 1971;14:134-44.
 4) Hill JR. Fistulas and fistulous abscesses in the anorectal region: personal experience in management. *Dis Colon Rectum* 1967;10:421-34.
 5) Chulani HL, Kulkarni MS. Quadruple anal fistula: report of a case. *Dis Colon Rectum* 1982;25:143-4.