

### Endoscopic Ultrasonography Versus Endoscopic Retrograde Cholangiopancreatography for the Diagnosis of Choledocholithiasis

Yun Mee Choi, M.D., Hae Sung Kim, M.D., Seung Ik Ahn, M.D., Keon Young Lee, M.D., Kee Chun Hong, M.D., Sun Keun Choi, M.D., Yoon Seok Hur, M.D., Sei Joong Kim, M.D., Ze Hong Woo, M.D., Seok Hwan Shin, M.D. and Hyung Gil Kim, M.D.<sup>1</sup>

**Purpose:** In order to reduce the rate of conversion to an open cholecystectomy, and to avoid the retention of bile duct stones, it is important to detect a choledocholithiasis prior to a laparoscopic cholecystectomy. The aim of this study was to compare the diagnostic accuracy of endoscopic ultrasonography (EUS) with endoscopic retrograde cholangiopancreatography (ERCP) in 150 patients who had an intraoperative cholangiography and choledochotomy with a choledocholithiasis performed.

**Methods:** Between January 2001 and February 2002, 150 patients who underwent an ERCP or EUS performed preoperatively and a cholecystectomy with intraoperative cholangiography or choledochotomy consecutively performed at the Inha University Hospital were reviewed.

**Results:** An ERCP was performed in 119 patients, and an EUS was carried out in 67 patients. Thirty six patients had both performed. The ERCP failed in 17cases (14.3%). The EUS identified the bile duct in all cases. There were five ERCP related complications (3 pancreatitis, 2 cholangitis), but no complications were encountered when using EUS. In 62 patients (41.3%), a choledocholithiasis was found. ERCP had a sensitivity of 89.5%, a specificity of 84.4%, a positive predictive value of 87.8%, and a negative predictive value of 86.4%. EUS showed a sensitivity of 88.9%, a specificity

of 84.7%, a positive predictive value of 66.7%, and a negative predictive value of 95.3%. Concordance of ERCP and EUS was obtained in 90% of cases.

**Conclusions:** EUS appears to be safer, more comfortable, and, as accurate as an ERCP detecting a choledocholithiasis. (J Korean Surg Soc 2003;64:327-331)

**Key Words:** EUS, ERCP, Choledocholithiasis

Departments of Surgery and <sup>1</sup>Internal Medicine, College of Medicine, Inha University, Incheon, Korea

374 7-206  
☎ 400-711,  
Tel: 032-890-3436, Fax: 032-890-3097  
E-mail: siahn@inha.ac.kr  
:2002 11 15 , :2002 12 24  
2002

가  
,  
(Endoscopic retrograde cholangiopancreatography;  
ERCP)  
가 .(1) ,  
가  
가 가  
가  
22~70% .(2-4)  
(endoscopic ultrasonography; EUS)  
가  
(5) EUS ERCP

2001 1 2002 2

715

6 mm

ERCp EUS 150

X

ERCp Olympus JF 230 TjF 230

EUS Olympus JF-UM 20 (7.5MHz)

150 119 ERCp 67

EUS 36 가

1)

41.3% 62

(Fig. 1), 88 (58.7%)

56.6 76:74

2) ERCp

150 119 17 14.3%

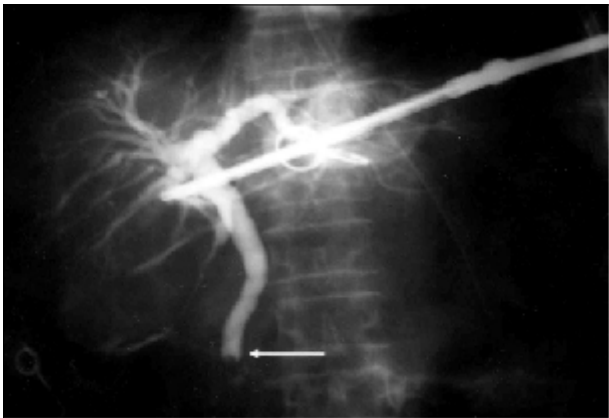


Fig. 1. Intraoperative cholangiography shows choledocholithiasis (arrow) during laparoscopic cholecystectomy.

가 119 2 3

2

가 102 57

, 45

(Table 1).

3) EUS

67

18

(Fig. 2), 49 (Table 2).

Table 1. Detection of choledocholithiasis by ERCp

ERCp diagnosis of choledocholithiasis	Final diagnosis of choledocholithiasis (no. of patients)	
	Positive	Negative
Positive	51	7
Negative	6	38

Table 2. Detection of choledocholithiasis by EUS

EUS diagnosis of choledocholithiasis	Final diagnosis of choledocholithiasis (no. of patients)	
	Positive	Negative
Positive	16	8
Negative	2	41

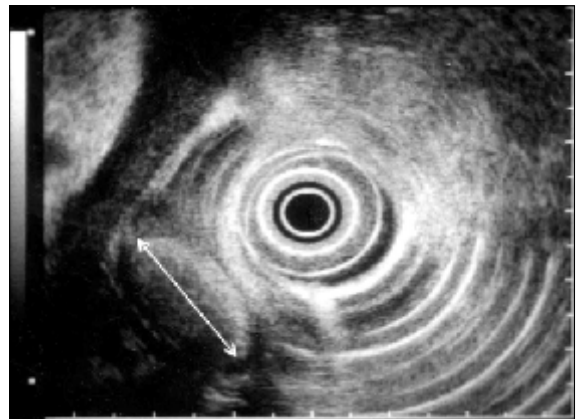


Fig. 2. EUS shows choledocholithiasis with stone diameter 1.7 cm (arrow).

**Table 3.** Comparison of ERCP and EUS in detection of choledocholithiasis

	Sensitivity (%)	Specificity (%)	Efficiency (%)	Positive predictive value (%)	Negative predictive value (%)
EUS	88.9	83.7	85.1	66.7	95.3
ERCP	89.5	84.4	87.3	87.9	86.4

4) ERCP EUS (Table 3) 가 2 . 150 3 ERCP  
 ERCP 84.4% , EUS 89.5% ,  
 88.9% , 84.7%  
 가 . ERCP  
 87.9% , 86.4% EUS 66.7% , 95.3% . 36 가  
 6 ERCP  
 30 가 (12) EUS ERCP Frossard 1  
 . 27 3 21%  
 90% . EUS  
 2.3 가 66.7%  
 가 24 EUS  
 16 66.7% 가  
 가  
 , , ERCP, EUS, EUS  
 Aubertin (13) EUS 100%  
 21% 가 .(6) EUS가 , Canto (8) EUS 98%  
 ERCP 가 . Lachter (14) EUS  
 84% 97% , (15) 132  
 90% .(7-10) EUS ERCP 90% EUS 89.3%  
 ,(11) ERCP ERCP 92.9%  
 ERCP EUS ERCP  
 EUS EUS  
 EUS  
 가 EUS 4 EUS ERCP 6  
 EUS ERCP ERCP 가  
 EUS  
 .(16-18)  
 30 3 90% EUS  
 ERCP EUS 가 1 EUS 가 Bilbao (22) ERCP .(19-21)  
 ERCP ERCP  
 , , , 3%

		30%	ERCP	EUS	150
	4.2%	14.3%			
Sugiyama, Atomi(23)	155		EUS,	ERCP	EUS
			, ERCP	가	ERCP가
가	가				
	EUS가				
Ed-	ERCP	가			
Ed-	mundowicz (7)	20			
		, ERCP, EUS			
EUS가 ERCP					
	EUS	ERCP			
	가	EUS			
		EUS			
		ERCP			
		41.3%			
		ERCP			
	ERCP				
	가	가			
(24)	544				
		ERCP			
	ERCP가				
	ERCP	EUS	, ERCP		

**REFERENCES**

- 1) Neoptolemos SP, Show DE, Carr-Locke DL. A multivariate analysis of pre-operative risk factors in patients with common bile duct stones. Implications for treatment. *Ann Surg* 1989; 209:157-61.
- 2) Cronan JJ. US diagnosis of choledocholithiasis: a reappraisal. *Radiology* 1986;161:133-4.
- 3) Metcalf AM, Ephgrave KS, Dean TR, Maher JW. Preoperative screening with ultrasonography for laparoscopic cholecystectomy: an alternative to routine intraoperative cholangiography. *Surgery* 1992;112:813-6.
- 4) Dong B, Chen M. Improved sonographic visualization of choledocholithiasis. *J Clin Ultrasound* 1987;15:185-90.
- 5) Amouyal P, Amouyal G, Levy P, Tuzet S, Palazzo L, Vilgrain V, et al. Diagnosis of choledocholithiasis by endoscopic ultrasonography. *Gastroenterology* 1994;106:1062-7.
- 6) Joo JH, Park CW, Song DW, Lee JS, Lee MS, Cho SW, et al. Efficiency of endoscopic ultrasonography in diagnosis of choledocholithiasis prior to laparoscopic cholecystectomy. *Korean J Gastroenterol* 1994;26:690-6.
- 7) Edmundowicz SA, Aliperti G, Middleton WD. Preliminary experience using endoscopic ultrasonography in the diagnosis of choledocholithiasis. *Endoscopy* 1992;24:774-8.
- 8) Canto M, Chak A, Stellato T, Silvas MV Jr. Endoscopic ultrasonography versus cholangiography for the diagnosis of choledocholithiasis. *Gastrointest Endosc* 1998;47:439-48.
- 9) Natterman C, Dancygier H. Endoscopic ultrasonography in obstructive jaundice. *Gastroenterology* 1991;100:330.
- 10) Burtin P, Carpentier S, Petit R. Endosonography in the diagnosis of extrahepatic cholestasis: accuracy and limits. *Gastroenterology* 1991;100:311.
- 11) Snady H, Cooperman A, Siegel J. Endoscopic ultrasonography compared with computed tomography with ERCP in patients with obstructive jaundice or small peri-pancreatic mass. *Gastrointest Endosc* 1992;38:27-34.
- 12) Frossard JL, Hadengue A, Amouyal G, Choury A, Marty O, Giostra E, et al. Choledocholithiasis: a prospective study of spontaneous common bile duct stone migration. *Gastrointest Endosc* 2000;51:175-9.
- 13) Aubertin JM, Levoir D, Bouillot JL, Becheur H, Bloch F, Aouad K, et al. Endoscopic ultrasonography immediately prior to laparoscopic cholecystectomy: a prospective evaluation. *Endoscopy* 1996;28:667-73.



- 14) Lachter J, Rubin A, Shiller M, Lavy A, Yasin K, Suissa A, et al. Linear EUS for bile duct stones. *Gastrointest Endosc* 2000;51:51-4.
  - 15) Shim CS, Joo JH, Park CW, Kim YS, Lee JS, Lee MS, et al. Effectiveness of endoscopic ultrasonography in the diagnosis of choledocholithiasis prior to laparoscopic cholecystectomy. *Endoscopy* 1995;27:428-32.
  - 16) Chak A, Hawes RH, Cooper GS, Hoffman B, Catalano MF, Wong RC, et al. Prospective assessment of the utility of EUS in the evaluation of gallstone pancreatitis. *Gastrointest Endosc* 1999;49:599-604.
  - 17) Sugiyama M, Atomi Y. Acute biliary pancreatitis: the roles of endoscopic ultrasonography and endoscopic retrograde cholangiopancreatography. *Surgery* 1998;124:14-21.
  - 18) Liu CL, Lo CM, Chan JK, Poon RT, Lam CM, Fan ST, et al. Detection of choledocholithiasis by EUS in acute pancreatitis: a prospective evaluation in 100 consecutive patients. *Gastrointest Endosc* 2001;54:325-30.
  - 19) Scheiman JM, Carlos RC, Barnett JL, Elta GH, Nostrant TT, Chey WD, et al. Can endoscopic ultrasound or magnetic resonance cholangiopancreatography replace ERCP in patients with suspected biliary disease? A prospective trial and cost analysis. *Am J Gastroenterol* 2001;96:2900-4.
  - 20) Zidi SH, Prat F, Le Guen O, Rondeau Y, Rocher L, Fritsch J, et al. Use of magnetic resonance cholangiography in the diagnosis of choledocholithiasis: prospective comparison with a reference imaging method. *Gut* 1999;44:118-22.
  - 21) Barish MA, Yucel EK, Ferrucci JT. Magnetic resonance cholangiopancreatography. *N Engl J Med* 1999;341:258-64.
  - 22) Bilbao MK, Dotter CT, Lee TG, Katon RM. Complications of endoscopic retrograde cholangiopancreatography (ERCP). A study of 10,000 cases. *Gastroenterology* 1976;70:314-20.
  - 23) Sugiyama M, Atomi Y. Endoscopic ultrasonography for diagnosing choledocholithiasis: a prospective comparative study with ultrasonography and computed tomography. *Gastrointest Endosc* 1997;45:143-6.
  - 24) Kim DK, Lee SM, Ko YG, Hong SW, Oh SM, Joo HZ, et al. Laparoscopic cholecystectomy after an endoscopic sphincterotomy for patients with choledocholithiasis. *J Korean Surg Soc* 1999;57:100-6.
-