

Sequential Chemoradiotherapy for Stage I/II Nasal Natural Killer/T Cell Lymphoma

Young Joo Noh, M.D.*[†], Yong Chan Ahn, M.D.[†], Won Seog Kim, M.D.[‡] and Young Hyeh Ko, M.D.[§]

*Department of Radiation Oncology, Ulsan University Hospital, University of Ulsan College of Medicine, Ulsan, Korea, Departments of [†]Radiation Oncology, [‡] Internal Medicine and [§]Diagnostic Pathology, Samsung Medical Center, Sungkyunkwan University School of Medicine, Seoul, Korea

Purpose: Authors would report the results of sequential CHOP chemotherapy (cyclophosphamide, adriamycin, vincristine, and prednisone) and involved field radiotherapy (IFRT) for early stage nasal natural killer/T-cell lymphoma (NKTCL).

Materials and Methods: Fourteen among 17 patients, who were registered at the Samsung Medical Center tumor registry with stage I and II nasal NKTCL from March 1995 to December 1999 received this treatment protocol. Three to four cycles of CHOP chemotherapy were given at 3 weeks' interval, which was followed by local IFRT including the known tumor extent and the adjacent draining lymphatics.

Results: Favorable responses after chemotherapy (before IFRT) were achievable only in seven patients (5 CR's+2 PR's: 50%), while seven patients showed disease progression. There were six patients with local failures, two with distant relapses, and none with regional lymphatic failure. The actuarial overall survival and progression-free survival at 3 years were 50.0% and 42.9%. All the failures and deaths occurred within 13 months of the treatment start. The factors that correlated with the improved survival were the absence of 'B' symptoms, the favorable response to chemotherapy and overall treatment, and the low risk by international prognostic index on univariate analyses.

Conclusion: Compared with the historic treatment results by IFRT either alone or followed by chemotherapy, the current trial failed to demonstrate advantages with respect to the failure pattern and survival. Development of new treatment strategy in combining IFRT and chemotherapy is required for improving outcomes.

Key Words: Lymphoma, Chemotherapy, Radiation therapy

Introduction

Nasal natural killer/T-cell lymphoma (NKTCL), formerly referred to as various synonyms of polymorphic reticulosis, lethal midline granuloma, or angiocentric lymphoma, is now regarded as a distinctive clinicopathological entity.¹⁾ There has been no one treatment strategy that is generally accepted as the most optimal in treating nasal NKTCL even at localized stages. Local involved field radiation therapy (IFRT), either

alone or followed by chemotherapy, used to be the traditional treatment approach for early stage nasal NKTCL. Upfront IFRT enabled apparently favorable initial response, but ultimately resulted in unsatisfactory survival outcomes with frequent relapses.^{2~4)} Local relapse was the major failure pattern, while the risk of systemic failure was also substantial. The high necessity of combined treatment approach using local IFRT plus systemic chemotherapy, therefore, was evident in this context.

Based on the results that showed the improved outcomes after adriamycin-containing combination chemotherapy followed by IFRT in early stage aggressive lymphomas, authors designed a protocol treatment consisting of sequential CHOP chemotherapy and IFRT in stage I/II nasal NKTCL since 1995.^{4~8)}

Submitted July 9, 2004, accepted September 7, 2004

Reprint request to Yong Chan Ahn, Department of Radiation Oncology, Samsung Medical Center, Sungkyunkwan University School of Medicine, 50 Ilwon-dong, Gangnam-gu, Seoul 135-710, Korea

Tel: 02)3410-2602, Fax: 02)3410-2619

E-mail: ycahn@smc.samsung.co.kr.

Materials and Methods

Seventeen patients with stage I/II nasal NKTCL were registered at the Samsung Medical Center tumor registry from March 1995 to December 1999. The diagnosis of nasal NKTCL was made based on the clinical presentation and the histopathologic examination. The reconfirmation of the histopathologic diagnosis was made by one of the coauthors (Y. H. Ko.) after retrospective review of all the histopathologic specimens without clinical information. The work-up's for Ann Arbor staging included thorough history and physical examination, complete blood counts, blood chemistry profiles, bone marrow aspiration and biopsies, computed tomography (CT) or magnetic resonance (MR) imaging of the head and neck, simple X-ray and/or CT scans of the chest, and CT scans of the abdomen and the pelvis. Data analyses were done on 14 patients who were treated along the current protocol consisting of sequential CHOP chemotherapy and IFRT.

The CHOP regimen consisted as follows: cyclophosphamide, 750 mg/m² i.v., on day 1; adriamycin, 50 mg/m² i.v., on day 1; vincristine, 1.4 mg/m² i.v., on day 1; and prednisone, 100 mg orally on days 1 to 5. Three to four cycles of CHOP chemotherapy were repeated at 3 weeks' interval, and IFRT was planned to start in 3 weeks of the last chemotherapy cycle. Authors used 4 MV X-rays from a linear accelerator. The IFRT volume included the known tumor extent and the immediate adjacent draining lymphatics. The typical IFRT portal arrangement for the patients with pharyngeal lesions was 2 lateral opposing fields, and that for those with nasal cavity and/or paranasal sinus involvement was 3 fields using one anterior and 2 lateral wedged fields after CT-based computerized RT planning. The IFRT fields were extended to the cervical neck lymphatics in the patients with gross cervical lymph node involvement. The fractionation schedule was to give 5 daily treatments per week. The fractional radiation dose was either 1.8 Gy or 2.0 Gy, which was individually determined depending on the radiation volume, where we chose 2.0 Gy per fraction for relatively small radiation volumes. The total radiation dose ranged from 44 Gy to 50.4 Gy (median dose=45 Gy), excluding one patient in whom the aim of IFRT was not curative but palliative for local progression (16 Gy).

Three patients were not treated per protocol based on the physicians' discretion, and were excluded from data analyses: two received concurrent chemoradiotherapy from the first chemotherapy cycle; and one received IFRT before chemotherapy for the control of profuse bleeding from the palate. The chemotherapy regimen and the IFRT technique of these three patients were basically the same as those in 14 patients receiving the protocol treatment.

Authors investigated the treatment compliance, the response to treatment, the patterns of failure, and the survival. The response to treatment was assessed according to the WHO response criteria based on the physical examination and the radiological findings obtained in one month of planned treatment. Further follow-up evaluations included the blood tests, chest X-rays, CT or MR scans of the head and neck at every 3 to 4 months' interval. The survival durations were calculated from the dates of the treatment start to the dates of events or the last clinical follow-up, and the survival rates were calculated using the Kaplan-Meier method on an intention-to-treat basis. Possible prognostic factors that might have influenced the survival rates were subjected to univariate analyses by log rank test, and the statistical significance was defined as p value less than 0.05. Factors analyzed included the gender, age, stage, 'B' symptom, international prognostic index (IPI), actually delivered treatment modality, response to chemotherapy and ultimate response.

Results

The characteristics of 14 patients are summarized in the Table 1. There were eight males and six females, and the median age was 41 years (range: 30~66 years). The primary sites of involvement were the Waldeyer's ring (oropharynx and nasopharynx) in eight patients (57.1%), the nasal cavity in four (28.6%), and the paranasal sinus in two (14.3%), respectively. Six patients had involvement of the overlapping neighboring structures (42.9%). The Ann Arbor stages were I_E in 11 patients (78.6%), and II_E in three patients who had cervical lymph node metastasis at the time of presentation (21.4%). Six patients had 'B' symptoms (42.9%). Eleven patients were with low risk (78.6%) and three were with intermediate risk (21.4%) by IPI.

This protocol treatment was commenced with the initial

CHOP chemotherapy in all 14 patients; IFRT, however, was not delivered in five patients (Table 2). The reasons for not giving IFRT were the compromised performance during chemotherapy in three patients and the strong patients' refusal of IFRT after achieving complete response in two. The numbers of chemotherapy cycles actually delivered were 2 cycles in four patients, 3 cycles in four, 4 cycles in four, and 6 cycles in two, respectively (Table 2). The reasons for

receiving less than 4 cycles were the poor response to chemotherapy, the compromised performance status, and the patients' refusal of further chemotherapy after experiencing severe side effect (i.e. neutropenic fever). Two patients who strongly refused IFRT after achieving favorable response to initial 4 cycles of CHOP chemotherapy were given additional 2 cycles of CHOP chemotherapy.

The response to CHOP chemotherapy was not so satisfactory as could be expected in lymphomas of other histologic types (Table 2): complete response (CR) in five patients; partial response (PR) in two; and progressive disease (PD) in seven, respectively. Nine patients received IFRT following CHOP chemotherapy per protocol. The response after IFRT was confounded by the response to CHOP chemotherapy, and, more or less, difficult to quantify. Three CR's and two PR's after CHOP chemotherapy were either maintained or converted to CR after the addition of IFRT, and four PD's after CHOP chemotherapy were converted to PR in three and to CR in one after IFRT. The ultimate overall responses were CR in eight patients (57.1%), PR in three (21.4%), and PD in three (21.4%), respectively.

The median follow-up period of all patients was 20 months, and that for those who survived was 32 months. There were eight patients who experienced treatment failures (six local failures, two distant relapses)(Table 2). One of the distant

Table 1. Clinical Characteristics of Patients

Characteristics	Number	(%)
Sex		
Male	8	57.1
Female	6	42.9
Primary sites of involvement		
Waldeyer's ring	8	57.1
Nasal cavity	4	28.6
Paranasal sinus extension	2	14.3
Stage		
I _E	11	78.6
II _E	3	21.4
'B' symptoms		
Absent	8	57.1
Present	6	42.9
International prognostic index		
Low	11	78.6
Intermediate	3	21.4

Table 2. Case Summary

Case	Age/ Sex	Stage	Sites involved*	Treatment †	IFRT dose (Gy/fractions)	Response ‡ to CHOP	Response to IFRT	Ultimate response	Initial recurrence	Follow-up § (months)
1	37/M	I _E	WR	CHOP #2 → IFRT	45/25	PR	CR	CR	-	NED (47)
2	49/F	II _{EB}	PNS, Neck	CHOP #4 → IFRT	45/25	CR	CR	CR	Cholangioca	NED (45)
3	62/F	I _E	NC+PNS	CHOP #4 → IFRT	50.4/28	CR	CR	CR	-	NED (32)
4	44/M	I _E	PNS+WR	CHOP #4 → IFRT	40/20	CR	CR	CR	-	NED (32)
5	39/F	I _E	NC	CHOP #4 → IFRT	50/25	PD	CR	CR	Local	NED (29)
6	32/F	I _E	WR	CHOP #3 → IFRT	50/25	PD	PR	PR	Liver, GI tract	DOD (13)
7	55/M	I _{EB}	WR+PNS	CHOP #3 → IFRT	44/22	PR	CR	CR	Skin	DOD (9)
8	30/M	I _{EB}	WR	CHOP #3 → IFRT	16/ 8	PD	PR	PR	Local	DOD (7)
9	41/M	I _{EB}	WR+PNS	CHOP #2 → IFRT	45/25	PD	PR	PR	Local	DOD (5)
10	41/M	I _E	WR	CHOP #6	-	CR	-	CR	-	NED (32)
11	41/F	I _E	NC+PNS	CHOP #6	-	CR	-	CR	-	NED (27)
12	39/M	II _{EB}	WR, Neck	CHOP #2	-	PD	-	PD	Local	DOD (7)
13	56/F	I _{EB}	NC	CHOP #3	-	PD	-	PD	Local	DOD (3)
14	66/M	II _{EB}	WR+PNS, Neck	CHOP #2	-	PD	-	PD	Local	DOD (2)

*WR: waldeyer's ring, PNS: paranasal sinus, NC: nasal cavity; † CHOP: chop chemotherapy, IFRT: involved field radiation therapy; ‡ CR: complete remission, PR: partial remission, PD: progressive disease; §NED: no evidence of disease, DOD: dead of disease

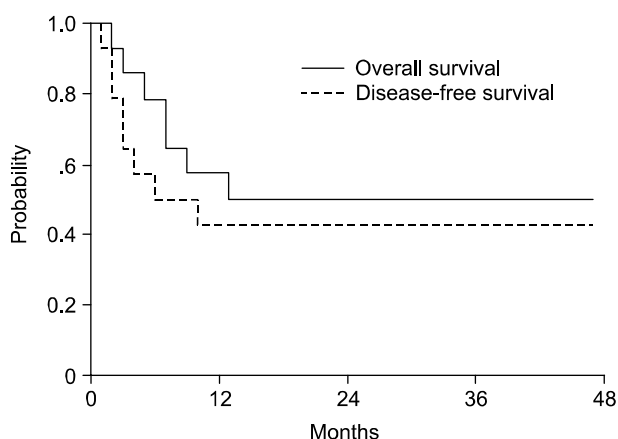


Fig. 1. Overall survival and progression-free survival rates at 3 years were 50.0% and 42.9%.

relapses was in the skin at 6 months, and another was in the liver and the gastrointestinal tract at 10 months, respectively. There was no regional lymphatic failure. Eight patients with recurrences were offered salvage treatment measures including various chemotherapeutic regimens and/or RT. Among them, only one was successfully salvaged, while seven died of disease. One patient who showed PD ultimately achieved CR at 13 months after local re-irradiation. One patient developed cholangiocarcinoma of the liver as new primary cancer at 43 months, which was managed with left lobectomy of the liver.

The overall survival and progression-free survival at 3 years were 50.0% and 42.9% (Fig. 1). All the failures and deaths occurred within 13 months of the treatment start, and the median durations until recurrence and death were 3 months and 7 months, respectively. Among those seven patients with 'B' symptoms, only one patient showed favorable outcome. In univariate analyses, the factors that correlated with the improved overall survival were the absence of 'B' symptoms, the favorable response to chemotherapy, the favorable ultimate response, and the low risk by IPI.

Discussion

Nasal NKTCL is more prevalent in Asian countries than in the Western, and the most common clinical presentation is destructive lesion characterized by infiltrative and necrotizing tumor affecting the nasal or the midline facial structures.^{1,2,9-14)}

This disease entity was previously referred to as various

synonyms of polymorphic reticulosis, lethal midline granuloma, progressive lethal granulomatous ulceration, malignant granuloma, and midline malignant reticulosis.^{9,12,15,16)} Histopathological characteristics usually included broad morphological spectrum, angiocentric growth pattern, and necrosis. These disease entities were considered as 'lymphoproliferative disorder' and as 'angiocentric lymphoma' in the past, based on the common features of angiocentricity and angiodestructive nature.^{1,17-19)} As 'angiocentricity', however, is not a constant feature, using the term 'angiocentric lymphoma' is no more appropriate.²⁰⁾ Immunophenotypically, this tumor expresses the phenotype of NK cell: positive for surface CD2, CD56, and cytoplasmic CD3; negative for surface CD3 and CD5.²¹⁻²⁴⁾ In the 1996's workshop report, it was concluded that nasal NKTCL was a distinct clinicopathologic entity highly associated with EBV, based on the constellation of histologic, clinical, immunophenotypic, and genotypic features.²⁰⁾ 'Nasal NKTCL' was classified as a distinct entity of peripheral T cell or NK cell lymphoma in the revised European-American Lymphoma Classification.²⁵⁾ Nasal NKTCL, however, may involve other aerodigestive tracts and other extranodal sites such as the gastrointestinal tract, the skin, and the testis.^{15,26-30)} Recently nasal and extranasal NKTCL was classified as 'extranodal NKTCL, nasal type' in the WHO classification.³¹⁾

There has been no general agreement as to the optimal treatment for localized stage nasal NKTCL. The reasons for this include the relative rarity in incidence, somewhat confusing terminology having been used, and the retrospective nature of the most reported literatures by non-uniform treatment methods. Local IFRT, in general, has been effective for localized stage non-Hodgkin's lymphomas. Several authors reported that moderate dose IFRT of 40 to 50 Gy to localized nasal NKTCL could lead to favorable response.^{1,2,20,32)} Kim et al reported that, after the median 50.4 Gy's IFRT, CR and PR were achieved in 63% and 17.4% of the patients, respectively.²⁾ The local relapse, however, was the major failure pattern despite the apparently favorable response to IFRT, and the incidence of systemic failures was also significant.^{1,2,12,33,34)} In Davison's study on 30 cases, 10 patients relapsed in the local site, and five did in the systemic sites.¹⁾ In Kim's report, half of the patients ultimately experienced the local recurrence, and the systemic failure

occurred in one-quarter of the patients.²⁾ It is evident that IFRT alone, despite the apparently favorable response, usually resulted in the high rates of the local as well as the systemic failures. Chemotherapy alone, meanwhile, was definitely inferior to IFRT and could not be the alternative option in treating early stage nasal NKTCL. According to the reports by Sobrevilla-Calvo et al, CR was achieved in 14 of 19 patients (74%) with 5 years survival rate of 70% in IFRT group, while CR was achieved only in four of ten patients (40%) with 1 year survival rate of only 15% in chemotherapy group, respectively.³⁵⁾ Several authors tried to combine chemotherapy and IFRT, and reported that the addition of chemotherapy did neither improve the survival significantly nor change the patterns of failure.^{12,33,36-38)}

The treatment scheme of our study was to evaluate whether the sequential CHOP chemotherapy and IFRT could lead to the equivalently favorable results and compliances to those achieved in early stage aggressive non-Hodgkin's lymphomas. As for local tumor response, the favorable responses of CR or PR were achieved only in half of the patients after CHOP chemotherapy before IFRT (7/14, 50%). The remaining half, on the other hand, experienced disease progression during CHOP chemotherapy cycles. The number of chemotherapy cycles actually delivered was mainly affected by the initial response and the patients' tolerance to CHOP chemotherapy. Only those who showed favorable responses to CHOP chemotherapy could complete the planned chemotherapy cycles and IFRT, while the unintended changes of treatment scheme were inevitable in those who showed unfavorable responses during CHOP chemotherapy. Summarizing our results, the response to CHOP chemotherapy was rather worse than those could be expected in aggressive non-Hodgkin's lymphomas. This unfavorable response to CHOP chemotherapy, in turn, led to the poor compliance to the overall treatment protocol. It was evident that the addition of IFRT certainly contributed to the improvement of the ultimate response, even after the unfavorable response to CHOP chemotherapy. Among seven patients in our study, who showed PD to CHOP chemotherapy, four received IFRT, while three did not. The responses after the addition of IFRT in four patients were one CR and three PR's. The ultimate objective response rate including CR and PR after completion of the planned treatment was 78.6% (11/14). The actuarial

overall survival and progression-free survival rates at 3 years, in this study, were 50.0% and 42.9%. These results were not significantly different from the data obtained after IFRT alone or IFRT followed by chemotherapy. This may imply that the current CHOP chemotherapy regimen in nasal NKTCL is not as effective as in aggressive non-Hodgkin's lymphomas, and that the response to CHOP chemotherapy serves only as a prognostic indicator of the overall survival. Yamaguchi et al suggested that the frequent expression of P-glycoprotein and multidrug resistance mRNA by nasal NKTCL be the explanation for the ineffectiveness of conventional chemotherapy regimens.³⁹⁾ Even though the reason for the heterogeneous response to CHOP chemotherapy is not clearly demonstrable in our study, the innate resistance to the current chemotherapy regimen may have influenced the response.

Based on the authors' observations, the response to CHOP chemotherapy did serve as an important prognostic indicator, and the addition of IFRT did contribute to the improvement of the overall response rate. Development of new treatment strategy to combine IFRT and chemotherapy is required for improving outcomes.

References

1. Davison SP, Habermann TM, Strickler JG, DeRemee RA, Earle JD, McDonald TJ. Nasal and nasopharyngeal angiocentric T-cell lymphomas. *Laryngoscope* 1996;106:139-143
2. Kim GE, Cho JH, Yang WI, et al. Angiocentric lymphoma of the head and neck: patterns of systemic failure after radiation treatment. *J Clin Oncol* 2000;18:54-63
3. Smalley SR, Cupps RE, Anderson JA, et al. Polymorphic reticulosis limited to the upper aerodigestive tract-natural history and radiotherapeutic considerations. *Int J Radiat Oncol Biol Phys* 1988;15:599-605
4. Kim JS, Ahn YC, Yun HG, Park CI. Primary Radiation Therapy of Polymorphic Reticulosis. *J Korean Soc Therapeut Radiol Oncol* 1991;9(1):111-116
5. Kaminski MS, Coleman CN, Colby TV, Cox RS, Rosenberg SA. Factors predicting survival in adults with stage I and II large-cell lymphoma treated with primary radiation therapy. *Ann Intern Med* 1986;104:747-756
6. Mauch P, Leonard R, Skarin A, et al. Improved survival following combined radiation therapy and chemotherapy for unfavorable prognosis stage I-II non-Hodgkin's lymphomas. *J Clin Oncol* 1985;3:1301-1308
7. Monfardini S, Banfi A, Bonadonna G, et al. Improved five year survival after combined radiotherapy-chemotherapy for stage I-II non-Hodgkin's lymphoma. *Int J Radiat Oncol Biol*

- Phys 1980;6:125-134
8. Nissen NI, Ersboll J, Hansen HS, et al. A randomized study of radiotherapy versus radiotherapy plus chemotherapy in stage I-II non-Hodgkin's lymphomas. *Cancer* 1983;52:1-7
 9. Aozasa K, Ohsawa M, Tajima K, et al. Nation-wide study of lethal midline granuloma in Japan: frequencies of Wegener's granulomatosis, polymorphic reticulosis, malignant lymphoma and other related conditions. *Int J Cancer* 1989;44:63-66
 10. Campo E, Cardesa A, Alos L, et al. Non-Hodgkin's lymphomas of nasal cavity and paranasal sinuses. An immunohistochemical study. *Am J Clin Pathol* 1991;96:184-190
 11. Fellbaum C, Hansmann ML, Lennert K. Malignant lymphomas of the nasal cavity and paranasal sinuses. *Pathol Anat Histopathol* 1989;414:399-405
 12. Ho FC, Choy D, Loke SL, et al. Polymorphic reticulosis and conventional lymphomas of the nose and upper aerodigestive tract: a clinicopathologic study of 70 cases, and immunophenotypic studies of 16 cases. *Hum Pathol* 1990;21:1041-1050
 13. Ng CS, Chan JK, Lo ST, Poon YF. Immunophenotypic analysis of non-Hodgkin's lymphomas in Chinese. A study of 75 cases in Hong Kong. *Pathology* 1986;18:419-425
 14. Wong DS, Fuller LM, Butler JJ, Shullenberger CC. Extranodal non-Hodgkin's lymphomas of the head and neck. *Am J Roent Radiol Ther Nucl Med* 1975;123:471-481
 15. Chan JK, Sin VC, Wong KF, et al. Nonnasal lymphoma expressing the natural killer cell marker CD56: a clinicopathologic study of 49 cases of an uncommon aggressive neoplasm. *Blood* 1997;89:4501-4513
 16. van Gorp J, Weiping L, Jacobse K, et al. Epstein-Barr virus in nasal T-cell lymphomas (polymorphic reticulosis/midline malignant reticulosis) in eastern China. *J Pathol* 1994;173:81-87
 17. Eichel BS, Harrison EG Jr, Devine KD, Scanlon PW, Brown HA. Primary lymphoma of the nose including a relationship to lethal midline granuloma. *Am J Surg* 1966;112:597-605
 18. Tsai TF, Su IJ, Lu YC, et al. Cutaneous angiocentric T-cell lymphoma associated with Epstein-Barr virus. *J Am Acad Dermatol* 1992;26:31-38
 19. Wong KF, Chan JK, Ng CS, Lee KC, Tsang WY, Cheung MM. CD56 (NKH1)-positive hemato-lymphoid malignancies: an aggressive neoplasm featuring frequent cutaneous/mucosal involvement, cytoplasmic azurophilic granules, and angiocentricity. *Hum Pathol* 1992;23:798-804
 20. Jaffe ES, Krenacs L, Kumar S, Kingma DW, Raffeld M. Extranodal peripheral T-cell and NK-cell neoplasms. *Am J Clin Pathol* 1999;111:S46-S55
 21. Chan JK, Tsang WY, Pau MY. Discordant CD3 expression in lymphomas when studied on frozen and paraffin sections. *Hum Pathol* 1995;26:1139-1143
 22. Jaffe ES. Classification of natural killer (NK) cell and NK-like T cell malignancies. *Blood* 1996;87:1207-1210
 23. Ng CS, Chan JK, Lo ST. Expression of natural killer cell markers in non-Hodgkin's lymphomas. *Hum Pathol* 1987;18:1257-1262
 24. Ohsawa M, Nakatsuka S, Kanno H, et al. Immunophenotypic and genotypic characterization of nasal lymphoma with polymorphic reticulosis morphology. *Int J Cancer* 1999;81:865-870
 25. Harris NL. Principles of the revised European-American Lymphoma Classification (from the International Lymphoma Study Group). *Ann Oncol* 1997;8(S2):11-16
 26. Chan JK, Tsang WY, Hui PK, et al. T-and T/natural killer-cell lymphomas of the salivary gland: a clinicopathologic, immunohistochemical and molecular study of six cases. *Hum Pathol* 1997;28:238-245
 27. Chan JK, Tsang WY, Lau WH, et al. Aggressive T/natural killer cell lymphoma presenting as testicular tumor. *Cancer* 1996;77:1198-1205
 28. Jaffe ES, Chan JK, Su IJ, et al. Report of the workshop on nasal and related extranodal angiocentric T/natural killer cell lymphomas. Definitions, differential diagnosis, and epidemiology. *Am J Surg Pathol* 1996; 20:103-111
 29. Nakamura S, Suchi T, Koshikawa T, et al. Clinicopathologic study of CD56 (NCAM)-positive angiocentric lymphoma occurring in sites other than the upper and lower respiratory tract. *Am J Surg Pathol* 1995;19:284-296
 30. Shneider B, Touloukian R, Hajjar F, Selsky C, Buckley P. Perianal ulceration. A novel manifestation of angiocentric lymphoma. *Dig Dis Sci* 1993;38:1162-1166
 31. Jaffe ES, Harris NL, Diebold J, Muller-Hermelink HS. World Health Organization classification of neoplastic disease of the hematopoietic and lymphoid Tissues. A progress report. *Am J Clin Pathol* 1999;111(S1):S8-12
 32. Halperin EC, Dosoretz DE, Goodman M, Wang CC. Radiotherapy of polymorphic reticulosis. *Br J Radiol* 1982;55:645-649
 33. Itami J, Itami M, Mikata A, et al. Non-Hodgkin's lymphoma confined to the nasal cavity: its relationship to the polymorphic reticulosis and results of radiation therapy. *Int J Radiat Oncol Biol Phys* 1991;20:797-802
 34. Tao Q, Ho FC, Loke SL, Srivastava G. Epstein-Barr virus is localized in the tumour cells of nasal lymphomas of NK, T or B cell type. *Int J Cancer* 1995;60:315-320
 35. Sobrevilla-Calvo P, Meneses A, Alfaro P, Bares JP, Amador J, Reynoso EE. Radiotherapy compared to chemotherapy as initial treatment of angiocentric centrofacial lymphoma (polymorphic reticulosis). *Acta Oncol* 1993;32:69-72
 36. Cheung MM, Chan JK, Lau WH, et al. Primary non-Hodgkin's lymphoma of the nose and nasopharynx: clinical features, tumor immunophenotype, and treatment outcome in 113 patients. *J Clin Oncol* 1998;16:70-77
 37. Li YX, Coucke PA, Li JY, et al. Primary non-Hodgkin's lymphoma of the nasal cavity: prognostic significance of paranasal extension and the role of radiotherapy and chemotherapy. *Cancer* 1998;83:449-456
 38. Liang R, Todd D, Chan TK, et al. Treatment outcome and prognostic factors for primary nasal lymphoma. *J Clin Oncol* 1995;13:666-670
 39. Yamaguchi M, Kita K, Miwa H, et al. Frequent expression of P-glycoprotein/MDR1 by nasal T-cell lymphoma cells. *Cancer* 1995;76:2351-2356

I/II 병기 비강 Natural Killer/T Cell 림프종에 대한 순차적 항암화학요법과 방사선치료

울산대학교 의과대학 울산의대부속병원 방사선종양학과*
성균관대학교 의과대학 삼성서울병원 방사선종양학과[†], 내과[‡], 진단병리과[§]

노영주*[†] · 안용찬[‡] · 김원석[‡] · 고영혜[§]

목적: 초기 병기 비강 natural killer/T-cell 림프종에 대한 CHOP 항암화학요법과 국소 방사선치료의 순차적 적용 결과를 보고하고자 한다.

대상 및 방법: 1995년 3월부터 1999년 12월 사이에 성균관의대 삼성서울병원 종양센터에 비강 I/II 병기 natural killer/T-cell 림프종으로 등록된 17명의 환자들 중 14명의 환자들에 대하여 순차적 항암화학요법과 방사선치료를 적용하였고 이들에 대한 분석을 시행하였다. 치료방침은 우선 CHOP 항암화학요법을 3주 간격으로 3~4회 시행한 후 5주간에 걸쳐 육안적 병변과 인접한 림프절 부위에 대한 국소 방사선치료를 추가하는 것이었다.

결과: 방사선치료의 시작 전에 시행한 국소종양의 항암화학요법에 대한 반응평가는 50%의 환자들에서 양호한 반응(완전관해 5명+부분관해 2명)을 보였고 나머지 50%의 환자들에서는 병변이 진행하였다. 6명의 환자에서 국소재발이 나타났는데 이들 중 2명은 원격전이를 동반하였고, 영역 림프절 재발을 수반한 경우는 없었다. 3년 생존율과 무병생존율은 50.0%와 42.9%였으며, 모든 사망과 재발사례는 치료개시 후 13개월 이내에 발생하였다. 예후인자의 단변량 분석에서 'B' 증상이 없는 경우, 항암화학요법과 전체 치료방침에 양호한 반응을 보인 경우, 국제예후지표상 저위험군 등이 양호한 생존율과 관련이 있었다.

결론: 본 연구의 치료방침에 의한 결과는 과거의 방사선치료 단독 또는 방사선치료 후 항암화학요법 추가에 따르는 결과들과 비교해 볼 때 재발양상과 생존율의 측면에서 유리한 점이 없었다. 따라서 방사선치료와 항암화학요법을 새로운 병용방법에 관한 연구개발이 요망된다.

핵심용어: 림프종, 항암화학요법, 방사선치료