

## Evaluation of Electron Boost Fields based on Surgical Clips and Operative Scars in Definitive Breast Irradiation

Rena Lee, Ph.D., Eunah Chung, Jihye Lee, M.D. and Hyunsuk Suh, M.D.

Department of Radiation Oncology, Ewha Womans University Mokdong Hospital, Seoul, Korea

**Purpose:** To evaluate the role of surgical clips and scars in determining electron boost field for early stage breast cancer undergoing conserving surgery and postoperative radiotherapy and to provide an optimal method in drawing the boost field.

**Materials and Methods:** Twenty patients who had 4~7 surgical clips in the excision cavity were selected for this study. The depth informations were obtained to determine electron energy by measuring the distance from the skin to chest wall (SCD) and to the clip implanted in the most posterior area of tumor bed. Three different electron fields were outlined on a simulation film. The radiological tumor bed was determined by connecting all the clips implanted during surgery. Clinical field (CF) was drawn by adding 3 cm margin around surgical scar. Surgical field (SF) was drawn by adding 2 cm margin around surgical clips and an ideal field (IF) was outlined by adding 2 cm margin around both scar and clips. These fields were digitized into our planning system to measure the area of each separate field. The areas of the three different electron boost fields were compared. Finally, surgical clips were contoured on axial CT images and dose volume histogram was plotted to investigate 3-dimensional coverage of the clips.

**Results:** The average depth difference between SCD and the maximal clip location was  $0.7 \pm 0.56$  cm. Greater difference of 5 mm or more was seen in 12 patients. The average shift between the borders of scar and clips were 1.7, 1.2, 1.2, and 0.9 cm in superior, inferior, medial, and lateral directions, respectively. The area of the CF was larger than SF and IF in 6/20 patients. In 15/20 patients, the area difference between SF and IF was less than 5%. One to three clips were seen outside the CF in 15/20 patients. In addition, dosimetrically inadequate coverage of clips (less than 80% of prescribed dose) were observed in 17/20 patients when CF was used as the boost field.

**Conclusion:** The electron field determined from clinical scar underestimates the tumor bed in superior-inferior direction significantly and thereby underdosing the tissue at risk. The electron field obtained from surgical clips alone dose not cover the entire scar properly. As a consequence, our technique, which combines the surgical clips and clinical scars in determining electron boost field, was proved to be effective in minimizing the geographical miss as well as normal tissue complications.

Key Words: Electron boost field, Surgical clips, Tumor bed, Breast cancer

### Introduction

Breast conserving therapy with lumpectomy followed by

Submitted September 13, 2005 accepted November 23, 2005  
This work was supported by Grant No. R04-2002-20143-0 from the Basic Rresearch Program of Korea Science & Engineering Foundation.

Reprint requests to Rena Lee, Ewha Womans University Mokdong Hospital, Department of Radiation Oncology, 911-1 Mok-dong, Yangcheon-gu, Seoul 158-710, Korea  
Tel: 02)2650-5337, Fax: 02)2654-0363  
E-mail: renalee@ewha.ac.kr

radiation therapy has become the standard method for treating early stage breast cancer. Irradiation technique after lumpectomy consists of whole breast irradiation at a total dose of up to 50.0 Gy followed by a supplemental boost to the tumor bed of up to 60.0 Gy. Despite the high tumor control rate in early stage breast cancer patients, the area of high risk for local failure has been shown to include the surgical path from the external incision to the tumor bed.<sup>1)</sup> The effect of boost dose in reducing the risk of local recurrence rate has been studied by many investigators and showed improvement in local control.<sup>2-6)</sup> There are three commonly used techniques for delivering the boost

dose. These include photon irradiation, electron irradiation and brachytherapy. Several studies demonstrated that tumor bed boost is effectively managed with these techniques.<sup>7,8)</sup>

Regardless of the types of boost techniques used, one of the most important factor affecting the outcome of the boost is the accurate localization of tumor bed. Numerous methods to identify the tumor bed have been suggested including the use of surgical scar, surgical clips, and CT or ultrasound. Although most widely used technique in determining electron boost field is to mark the external surgical scar clinically, geographical miss of the tumor bed was observed<sup>9-12)</sup> Solin et al<sup>13)</sup> suggested a method for accurate localization of tumor bed by implanting surgical clips in the excision cavity during surgery. These studies documented that the placement of clips allow a precise determination of the tumor bed and found a potential errors of 40 to 70% between clinically determined and clip-verified topography of a tumor bed.

Aims of this work is to evaluate the role of surgical clips and scars in determining the electron boost field, to quantify dosimetric and geometric misses of the clips using the three dimensional treatment planning system, and to suggest an ideal method of determining boost fields for the treatment of breast using electron beam.

## Materials and Methods

Twenty patients with early stage breast cancer were involved in this study. All patients were candidates for breast conserving therapy with whole breast irradiation and electron boost following lumpectomy. In our hospital, four to six clips were implanted at the margins of the tumor bed during the surgery (medial, lateral, superior, inferior, at the center, and at the deepest portion of the tumor bed from the external excision). These clips were used as a reference for both tangential and electron boost treatments.

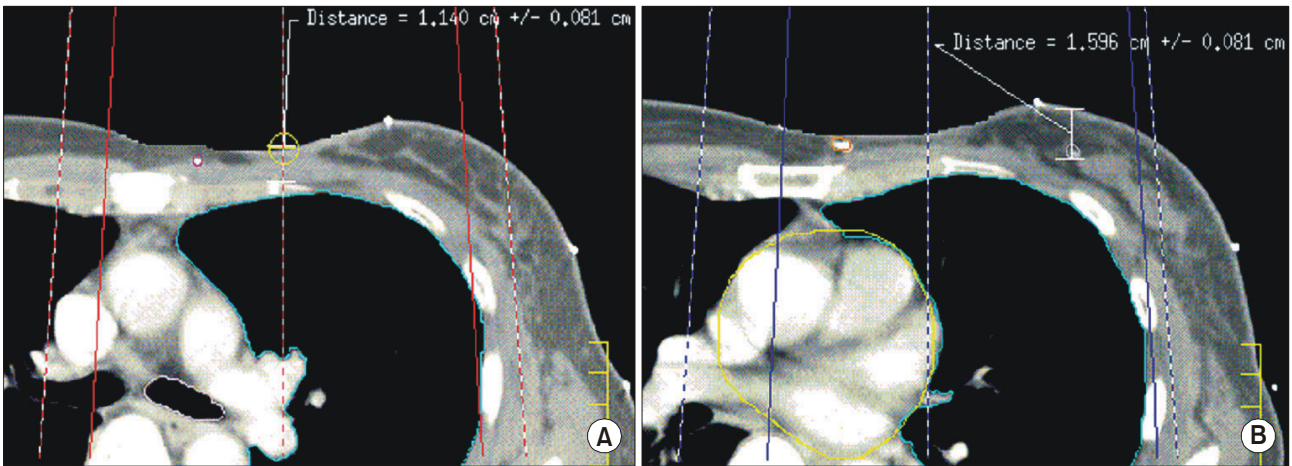
Patients were positioned on a board which was inclined to have the sternum as close to horizontal as possible in a supine position and simulation films were taken for tangential treatment. At the time of CT scan, the lumpectomy scar was marked with radio-opaque wire and the patients underwent CT scanning at 5 mm intervals with a commercial 16-slice CT scanner. All patients received whole breast irradiation to a total dose of 50.4 Gy over 5 weeks using 6MV photons using opposed

tangents. This was followed by a boost to the tumor bed in all patients with an additional dose of 10.0 Gy. Prior to completion of whole breast treatment, lumpectomy scar was marked with radio-opaque wire and simulation film was taken for electron boost field. Gantry angle was chosen so that the electron field is orthogonal to the skin surface and treatment depth was determined from the orthogonal film taken during simulation process. To determine electron energy for treatment, maximal clip depth was obtained from the digitally reconstructed radiography (DRR) at the treatment angle and the surface to the chest wall distance (SCD) through the center of the clinically determined electron field was measured (Fig. 1). After the depth to surgical clips and SCD have been determined, the appropriate electron energy was selected to adequately cover the tumor bed.

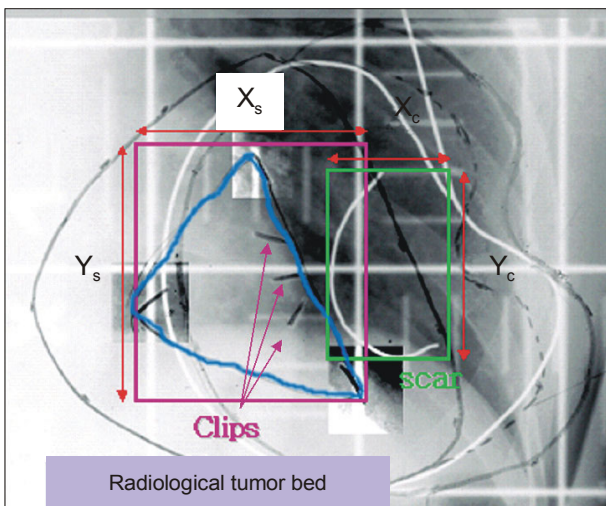
The location of surgical clips and lumpectomy scar were identified and marked on both simulation film and CT data (Fig. 2). The radiological determination of the tumor bed was based on the position of the clips. As shown in Fig. 2, the tumor bed was defined by connecting all the clips implanted in superior, inferior, medial and lateral directions. Two rectangles were drawn on simulation film enclosing the scar and the tumor bed. Differences in superior, inferior, medial, and lateral borders of the two rectangles were then calculated.

Three different boost fields were outlined on simulation film for evaluation as shown in Fig. 3. Clinical field (CF) border was determined from the surgical scar with a margin of 3 cm. Surgical field (SF) was determined by adding 2 cm margin around surgical clips. In the ideal field (IF), the treatment area included the clips and lumpectomy scar with a margin of 2 cm. The areas of the clinical, surgical, and ideal fields on the simulation film taken at the treatment angle were measured by means of an area measuring software and compared. All measurements were done in two dimensions. In addition to the area measurements, the number and location of clips missed in the clinical fields were defined. A clip was considered as a missed one if it was located on the clinically defined field margin (Fig. 2).

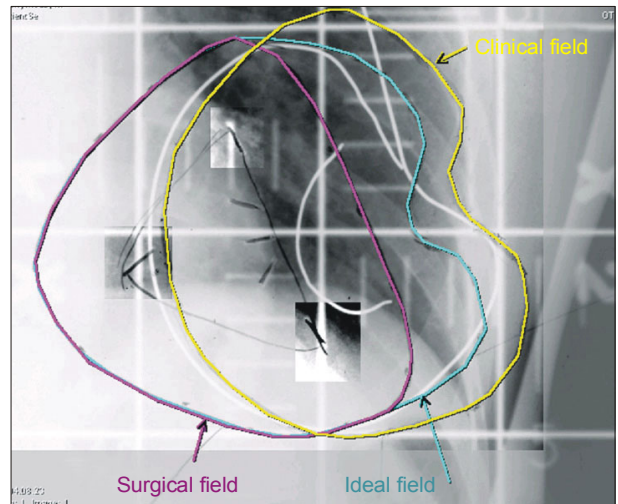
Finally, 3D radiotherapy planning system (Pinnacle, ADAC) was used for calculation of isodose curve to analyze dosimetric coverage of the clips. Clinical electron blocks were digitized into the planning system and radiation dose was calculated (Fig. 4). The number of clips receiving less than 80% of the prescribed dose were counted.



**Fig. 1.** CT slices of patient 8 (A) through the center of the electron field showing the skin to chest wall distance (SCD), (B) showing the deepest clip distance.



**Fig. 2.** Simulation film showing lumpectomy scar and surgical clips. (the enclosed area is the radiologically determined tumor bed, one clip is on the clinically defined field border).  $X_s$ : width of surgical field,  $Y_s$ : height of clip-based surgical field,  $X_c$ : width of clinical field,  $Y_c$ : height of scar-based clinical field.



**Fig. 3.** Simulation film showing clinical, surgical, and an ideal fields for electron boost treatment.

## Results

The maximum and minimum differences between the maximal clip depth and SCD were 2.1 cm and 0.1 cm with a mean value of  $0.7 \pm 0.56$  cm (Fig. 5). Greater difference of 5 mm or more was seen in 12 patients (60%).

The histogram of clip dispersal relative to the surgical scar in superior, interior, lateral, and medial directions showed that

the shifts between the borders of the surgical scar and tumor bed in lateral and medial directions are less than 1.0 cm in more than 50% of the patients (Fig. 6). The median values with standard deviations are  $1.7 \pm 0.9$  cm in superior direction,  $1.2 \pm 1.1$  cm in inferior direction,  $1.2 \pm 1.1$  cm in medial direction, and  $0.9 \pm 0.8$  cm in lateral direction. Largest shift is observed in superior direction.

The areas of the tumor bed, clinical, surgical, and ideal fields are shown in Table 1. The average area of the radiologically determined tumor bed which was based on the position of the clips were  $21.3 \pm 9.0$  cm<sup>2</sup>. This area equals to an area of  $4.6 \times 4.6$  cm square. The average areas of the CF, SF, and IF are

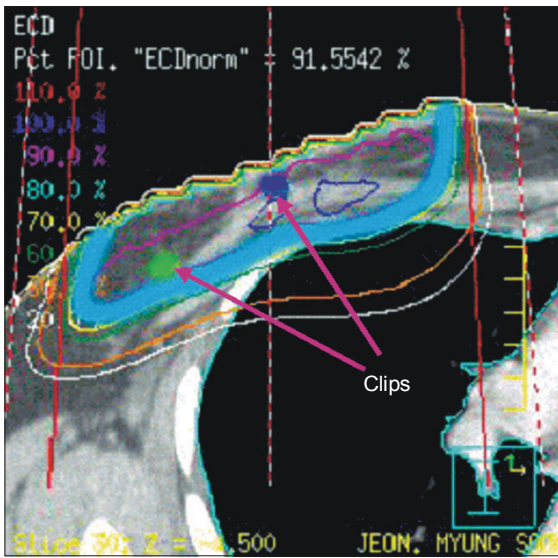


Fig. 4. Isodose distribution of a patient treated with 9 MeV electron beams.

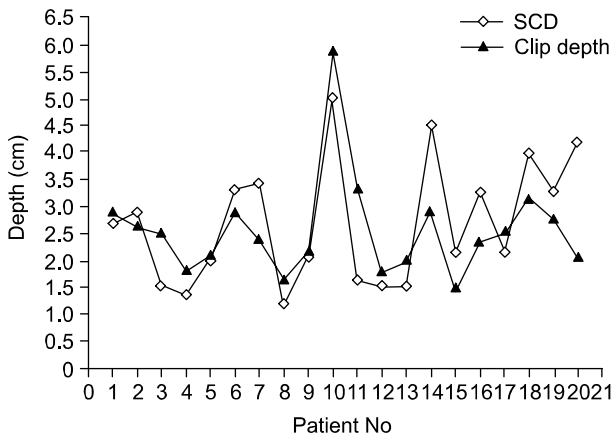


Fig. 5. The maximal clip depth and SCD.

66.2±7.4 cm<sup>2</sup>, 69.3±15.8 cm<sup>2</sup>, and 70.9±14.5 cm<sup>2</sup>, respectively. There was 4.4 % increase in total irradiated area when the average area of SF was compared to that of CF. In addition, 6.6 % increase was seen if the IF was compared to that of CF. The average irradiated area between SF and IF was similar (69.3 versus 70.9 cm<sup>2</sup>).

The CF was judged to be inadequate and required adjustment in most of the patients, resulting in a smaller surgical field in 6 patients and smaller ideal field in 3 patients. Minor modification (less than 5% change in area) was made in 4 patients and did not influence the SF and IF as much. Of the 20 patients, discrepancies between the clinical assumption and

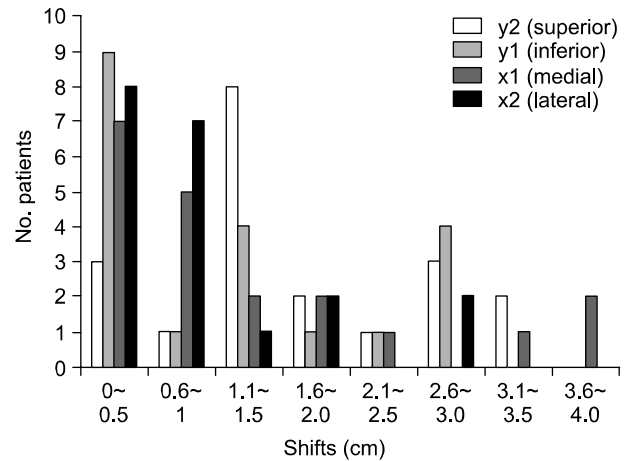


Fig. 6. Histogram of clip dispersal relative to the surgical scar in superior, inferior, lateral, and medial directions.

the radiological verification led to a major change in the boost design in 15 cases (75%). The discrepancies between the location of the surgical scar with respect to the clips led to an increase in the area of ideal field because it is required to include both lumpectomy scar and tumor bed in electron boost.

The clinically marked boost field didn't include all the surgical clips, so geographically missed in 15 patients (75%). Of those, the clips implanted in the superior border of the tumor bed were missed at the most (8/15 patients). In 17 patients, 1 to 5 clips were located at the area receiving less than 80% of the prescribed dose and dosimetrically missed, if clinical field is used as a electron boost. If the number of geographically missed clips were compared to the number of dosimetrically missed clip, there was significant difference (23 over 31 clips).

### Discussion

We performed depth measurements to determine the electron energy that covers the indicated depth of the tumor bed as measured by clips. The electron beam energy was chosen using the percent depth dose (PDD) tables for our linear accelerator (Primus<sup>®</sup>, Siemens, U.S.A.) machine so that the 80% isodose line covers the indicated depth of the target. The electron energies selected based on the SCDs were inadequately low in 6 (30%) and high in 9 of 20 patients when they were compared to the energies determined from the clip implanted in the posterior border of the tumor bed. This would result in a geographic miss or over exposure of the posterior tissues in

Table 1. Areas of the Tumor Bed, Clinical Field(CF), Surgical Field(SF), Ideal Field (IF) and Number of Clips Missed by Clinical Field

Patient no	TB (cm <sup>2</sup> )	CF (cm <sup>2</sup> )	SF (cm <sup>2</sup> )	IF (cm <sup>2</sup> )	Geographically missed		Dosimetrically missed
					Number	Direction	Number
1	32	68.5	88.5	89.4	2	S, L	3
2	18.2	60.4	62.7	63.9	1	L	1
3	26.9	76.7	83.1	84.7	3	M	5
4	22.5	61.4	71	71	0	N/A	0
5	32.7	66.4	89.8	89.8	2	S, L	2
6	19.4	62.3	67.2	67.2	0	S	0
7	11.8	57.7	50.5	56.4	1	L	1
8	46.1	75.4	108.1	108.4	2	L, I	2
9	11.3	59.8	48.4	52.3	1	M	1
10	20.1	61	70.5	72	3	L, M, S	4
11	30.1	78.6	87.1	87.1	1	S	2
12	21.6	61.9	68.9	58.9	1	S	1
13	11.1	61.6	63.8	66.6	1	M	2
14	17.3	71.8	61.1	68.3	1	I	1
15	21.3	56.9	66.8	67.3	1	S	1
16	13.5	73.4	55	58.9	0	N/A	1
17	26.2	78.1	78.1	78.1	0	N/A	2
18	10	62.3	46	55.1	0	I	0
19	16.9	57.5	58.9	60.3	1	M	1
20	17	72.7	59.9	62.3	2	S, I	1

more than one-half of patients treated when clips are not used as the guide for breast boost planning.

The true value of a breast boost following the whole breast treatment has yet to be determined. However, it still remains a commonly used method of treating breast cancer. In order for the additional electron dose to have any value, it is essential to deliver the accurate dose to the tissues at high risk for residual sites. Therefore, the most important task in adding the boost dose is the accurate determination of lumpectomy cavity with respect to the skin surface.

In the current study, we retrospectively analyzed our method of treating early stage breast cancer patients with electron beams to determine whether the CF affected the dosimetric coverage of the tumor bed. When the average area of SF was compared to that of CF, only 4% increase in total irradiated area was observed. However, in 17 of the 20 treated patients, 1 to 5 clips were missed in CF dosimetrically. These results suggest several major advantages to using our technique compared to the clinically defined fields. First, it was possible to define tumor bed using the surgical clips thus ensuring adequate coverage of the treatment target. Regine et al<sup>10)</sup> reported that 12 patients out of 17 patients showed inadequate inclusion of the surgical clips when the electron boost volume were defined clinically. This high proportion of geo-

graphic misses associated with the CF was also seen in our study. Second, it was possible to spare the normal tissue. Normal tissue sparing was improved in 7 of the twenty patients.

Using surgical scar alone is a highly inaccurate and unreliable method for identifying the dimensions of the tumor bed. Therefore, the role of additional dose would be minimal if it is used to guide the design of breast boost fields. Since significant portion of recurrences were seen within the margins of the initial tumor bed,<sup>14)</sup> we recommend to add 2 cm margin around clips and surgical scar and perform CT based treatment planning when a boost irradiation is intended. The 2 cm margin was added empirically on the basis that it was likely to provide adequate planning target volume with an allowance for normalization of the electron boost field. In conclusion, the IF is the best choice for drawing the electron boost field because surgical scars are poor indicators of location of the excision cavity and CF does not cover the surgical clips appropriately.

References

1. Solin L. Radiation treatment volumes and doses for patients with early stage carcinoma of the breast treated with breast conserving surgery and definitive irradiation. *Semin Radiat Oncol* 1992;2:82-93

2. Polgar C, Major T, Fodor J, et al. High-dose-rate brachytherapy alone versus whole breast radiotherapy with or without tumor bed boost after breast-conserving surgery: seven-year results of a comparative study. *Int J Radiat Oncol Biol Phys* 2004;60:1173-1181
3. Vicini F, Kini VR, Chen P, et al. Irradiation of the tumor bed alone after lumpectomy in selected patients with early-stage breast cancer treated with breast conserving therapy. *J Surg Oncol* 1999;70:33-40
4. Bartelink H, Collette L, Fourquet A, et al. Impact of a boost dose of 16 Gy on the local control and cosmesis in patients with early breast cancer: the EORTC boost vs no boost trial. *Int J Radiat Oncol Biol Phys* 2000;48:111
5. Bartelink H, Horiot JC, Poortmans P, et al. Recurrence rates after treatment of breast cancer with standard radiotherapy with or without additional radiation. *N Engl J Med* 2001;345:1378-1387
6. Harris JR, Botnick L, Bloomer WD, et al. Primary radiation therapy for early breast cancer: The experience at the Joint Center for Radiation Therapy. *Int J Radiat Oncol Biol Phys* 1981; 7:1549-1552
7. Poortmans P, Bartelink H, Horiot JC, et al. The influence of the boost technique on local control in breast conserving treatment in the EORTC 'boost versus no boost' randomised trial. *Radiother Oncol* 2004;72:25-33
8. Frazier RC, Kestin LL, Kini V, et al. Impact of boost technique on outcome in early-stage breast cancer patients treated with breast-conserving therapy. *Am J Clin Oncol* 2001;24:26-32
9. Denham JW, Carter ML. Conservative treatment of breast cancer-Where should the booster does go? *Int J Radiat Oncol Biol Phys* 1988;14:399-401
10. Regine WF, Ayyanger KM, Komarnickyk LT, Bhabdare N, Mansfield CM. Computer CT-planning of the electron boost in definitive breast irradiation. *Int J Radiat Oncol Biol Phys* 1991;20: 121-125
11. Machtay M, Lanciano R, Hoffman J, Hanks GE. Inaccuracies in using the lumpectomy scar for planning electron boosts in primary breast carcinoma. *Int J Radiat Oncol Biol Phys* 1994; 30:43-48
12. Harrington KJ, Harrison R, Bayle P, et al. Surgical clips in planning the electron boost in breast cancer: a qualitative and quantitative evaluation. *Int J Radiat Oncol Biol Phys* 1996;34: 579-584
13. Solin L, Danoff BF, Schwartz GF, Galvin JM, Goodman RL. A practical technique for the localization of the tumor volume in definitive irradiation of the breast. *Int J Radiat Oncol Biol Phys* 1985;11:1215-1220
14. Fisher ER, Sass R, Fisher B, Gregorio R, Brown R, Wickerham L. Pathologic findings from the national Surgical adjuvant breast project II. Relation of local breast recurrence to multicentricity. *Cancer* 1986;57:1717-1724

## 유방보존술 후 방사선치료에서 수술 흉터와 삽입된 클립을 이용한 전자선 추가 방사선 조사야 평가

이화여자대학교 의과대학 방사선종양학교실

이레나·정은아·이지혜·서현숙

**목적:** 본 연구에서는 초기 유방암환자에서 보존적 수술 후 전자선을 이용한 추가방사선 조사 시 조사야의 범위 결정에 수술상흔 및 외과적 클립이 미치는 역할을 분석하였으며 이상적인 조사야 범위 결정방법을 제시하였다.

**대상 및 방법:** 조기 유방암 환자로 병소를 제거한 후 외과적 클립을 4~7개 삽입한 환자 20명을 대상으로 연구를 시행하였다. 전자선의 치료 에너지를 결정하기 위하여 피부에서부터 흉부벽까지의 거리(SCD)와 병변 조직의 가장 뒤쪽에 위치해 있는 클립까지의 거리를 측정하였다. 수술시 삽입된 클립들을 simulation 필름 상에서 연결하여 방사선학적 tumor bed로 정의하였다. 방사선 조사야의 범위는 3가지 방법에 의해 simulation 필름에 그렸다. 임상방사선 조사야(CF)는 수술 상흔 둘레로 3 cm의 여유를 주었고, 외과적방사선 조사야(SF)는 클립주위로 2 cm의 여유를 주었으며, 마지막으로 이상적 방사선조사야(IF)는 수술 상흔과 클립을 모두 포함하여 2 cm의 여유를 주었다. 그려진 조사야들의 면적을 측정하기 위하여 치료계획 컴퓨터에 입력되었고 측정된 면적을 비교하였다. 마지막으로 삽입된 클립들을 CT 상에서 그려 넣었고 클립들의 3차원적인 선량분포를 알아보기 위해 선량체적표를 얻었다.

**결과:** SCD와 가장 깊이 삽입된 clip까지의 거리의 평균차이는  $0.7 \pm 0.56$  cm이다. 12명의 환자의 경우 깊이의 차이가 있다. 수술 상흔과 클립들의 평균 위치의 변화는 상방으로 1.7 cm, 하방으로 1.2 cm, 내측으로 1.2 cm, 그리고 외측으로 0.9 cm이다. CF의 면적은 20명의 환자 중 6명의 경우 SF보다 크고 IF보다 크다. SF와 IF의 면적 차이는 15의 환자에서 5%보다 작다. CF 조사야를 이용할 경우 15명의 환자들에 대해 1개 또는 3개의 클립들을 조사야 내에 포함하지 못하고 있다. 또한 클립들의 선량분포를 볼 때 17명의 환자들이 처방선량의 80% 미만을 받는 즉 선량적으로 부적절한 선량을 받는 클립들이 있었다.

**결론:** 수술 상흔을 중심으로 방사선 조사야 범위를 결정 할 경우 병변의 상하 부위를 적절히 포함하지 못하므로 병변 조직의 충분한 선량을 전달하지 못하였다. 외과적 클립만을 이용할 경우는 수술 상흔을 모두 포함하지 못하였다. 따라서 결론적으로 즉 수술 상흔과 외과적 클립을 모두 포함하는 본 기관에서 사용하는 방법으로 전자선 추가 조사야를 그린다면 정상조직의 부작용 및 지리상으로 병변조직의 빠트림을 최소화할 수 있을 것이다.

핵심용어: 전자선, 추가방사선 조사, 외과적 클립, 수술상흔, 초기 유방암