

- Abstract -

A Case of Pure Trigeminal Motor Neuropathy

Sang-Beom Kim, M.D., Gue-Yong Lee, M.D., Jung-Ho Seo, M.D., Jung-Yong Ahn, M.D.*,
Pyeong Ho Yoon, M.D.†, Byung-Ok Choi, M.D., Ok-Joon Kim, M.D.

Department of Neurology, Neurosurgery*, Radiology†, Pochon CHA University, College of Medicine, Sunnam, Korea

Pure trigeminal motor neuropathy is a trigeminal motor dysfunction, unaccompanied by trigeminal sensory signs and without affecting other cranial nerves. A 61-year-old woman was found to have left hemifacial swelling and trigeminal motor paralysis without sensory symptoms. Blink reflex and trigeminal nerve somatosensory evoked potentials were normal. Needle electromyographic examination showed neurogenic changes in the left temporalis and masseter muscles. Brain MRI revealed wasting and fatty degeneration of muscles innervated by trigeminal nerve. We report here on a case of pure trigeminal motor neuropathy with a review of the literature.

Key Words : Trigeminal nerve, Motor neuropathy, Fatty degeneration

. 3

1

, , , , , 61 가 3

, , , , , 가

. 1 가 , , , , ,

1

Address reprint requests to Ok-Joon Kim, M.D.
Department of Neurology, Pochon CHA University College of Medicine
351 Yatap-dong, Pundang-gu, Sunnam 463-712, Korea
Tel : 82-31-780-5481, Fax : 82-31-780-6200, E-mail : okjun77@cha.ac.kr

(Fig. 1).

6

가

1

, lupus anticoagulant, antineutrophil cytoplasmic antibody(ANCA), antinuclear antibody(ANA), (IgG), HIV , VDRL, rheumatoid factor , angiotensin-converting enzyme, anti-GM1 ,

가

0/mm³, 0/mm³, 74 mg/dL
가 . IgG index 0.486

, oligoclonal band

12

T1

, T2

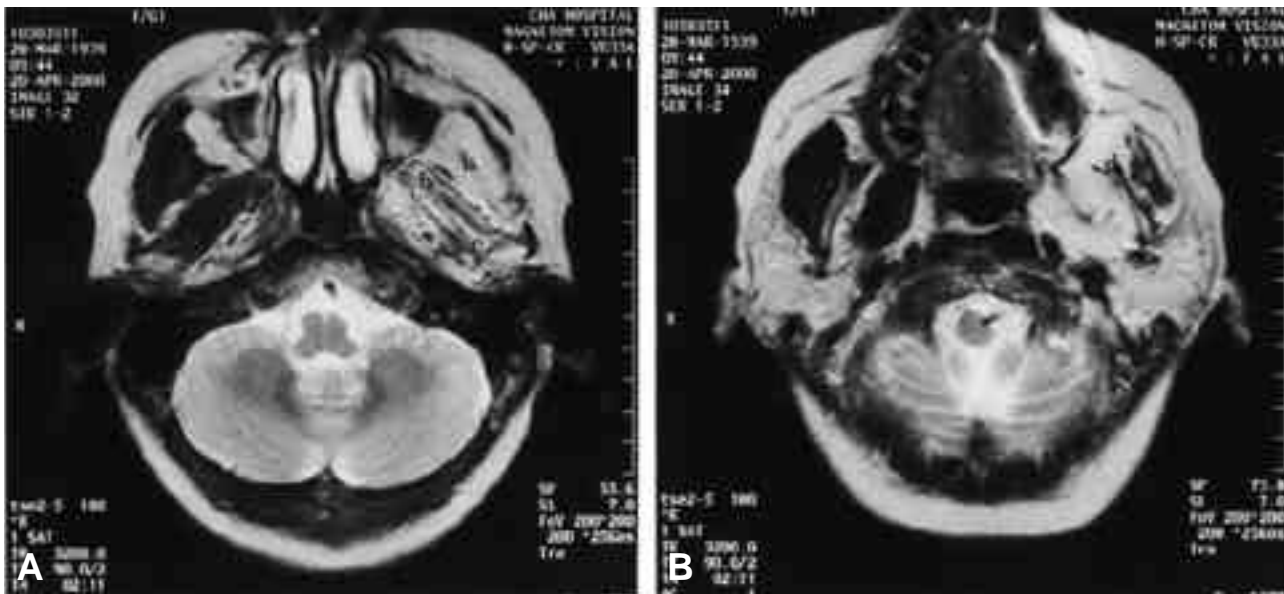


Fig. 1. Magnetic resonance image. Wasting and fat replacement of muscles innervated by trigeminal nerve: (a) temporalis, (b) lateral pterygoid, (c) medial pterygoid, and (d) masseter muscle(A & B axial T2WI).

, , , Guillain-Barre
 , , Charcot-Marie-Tooth , ,
 , .
 ,
 ,¹²
 , , , 2 .
 , ,^{1,2} motor nucleus chronic inflammatory demyelinating polyneuropathy(CIDP)
 , , , IgG index 가 ,
 , ,¹³ 1
 . 가
 . choline acetylase
 가 , acetylcholinesterase 가
 .
 .⁵ monosialo GM1 immunoglobulin M
 가 .⁶
 , synaptobrevin , synaptobrevin I gadolinium T2
 , synaptobrevin II ,
 .⁷ 가
 , ,
 .¹ 가 T1 가 T2¹⁴ 가
 .⁴
 . Chang Mulford 가 가
 .
 .⁸ Goldstein 48%¹² ,
 61³
 29 ,
 ,
 .⁹ 가 , , 가
 , 가 가
 , 가 가^{1,2,13}
 , 가
 ,¹⁰
 가¹¹ .

REFERENCES

1. Kang YK, Lee EH, Hwang M: Pure trigeminal motor neuropathy: a case report. *Arch Phys Med Rehabil* 2000; 81: 995-998
2. Ko KF, Chan KL: A case of isolated pure trigeminal motor neuropathy. *Clin Neurol Neurosurg* 1997; 2: 199-200
3. Shotts RH, Porter SR, Kumar N, Scully C: Longstanding trigeminal sensory neuropathy of nontraumatic cause. *Oral surg oral med oral pathol oral radiol endod* 1999; 87: 572-576
4. Dominguez J, Lobato RD, Madero S, Benito-Leon J, Rivas JJ, Gomez PA: Surgical findings in idiopathic trigeminal neuropathy mimicking a trigeminal neurinoma. *Acta Neurochir(Wien)* 1999; 141: 269-272
5. Engel J, Ganel A, Melamed R, Simon S, Farine I: Choline acetyltransferase for differentiation between human motor and sensory nerve fibers. *Ann Plastic Surg* 980; 4: 376-380
6. Taylor BV, Gross L, Windebank AJ: The sensitivity and specificity of anti-GM1 antibody testing. *Neurology* 1996; 47: 951-955
7. Li JY, Edelmann L, Jahn R, Dahlstrom A: Axonal transport and distribution of synaptobrevin I and II in the rat peripheral nervous system. *J Neurosci* 1996; 16: 137-147
8. Chang WK, Mulford GJ: Iatrogenic trigeminal sensorimotor neuropathy resulting from local anesthesia: a case report. *Arch Phys Med Rehabil* 2000; 81: 1591-1593
9. Goldstein NP, Gibilisco JA, Rushton JG: Trigeminal neuropathy and neuritis. *J Am med Ass* 1963; 184: 458-462
10. Campbell WW, Vasconcelos O, Laine FJ: Focal atrophy of the multifidus muscle in lumbosacral radiculopathy. *Muscle Nerve* 1998; 21: 1350-1353
11. Petersilge CA, Pathria MN, Gentili A, Recht MP, Resnick D: Denervation hypertrophy of muscle: MR features. *J Comput Assist Tomogr* 1995; 19: 596-600
12. Seidel E, Hansen C, Urban PP, Vogt T, Muller-Forell W, Hopf HC: Idiopathic trigeminal sensory neuropathy with gadolinium enhancement in the cisternal segment. *Neurology* 2000; 54: 1191-1192
13. , , , , : 1 . 1993; 12: 555-558
14. Sevick RJ, Dillon WP, Engstrom J, Bergman WP, Harnsberger HR: Trigeminal neuropathy. Gd-DTPA enhanced MR imaging. *J Comput Assist Tomogr* 1991; 15: 605-611