

Chronic Subdural Strip Electrode Recordings as Preoperative Evaluation for Epilepsy Surgery

난치성 간질환자의 수술전 검사에서 뇌경막하 전극의 이용에 관한 임상연구

Eun-Ik Son, M.D.¹, Il Man Kim, M.D.¹, Sang Do Yi, M.D.²,
Ji Eun Kim, M.D.² and Chang Young Lee, M.D.¹
손은익¹ · 김일만¹ · 이상도² · 김지연² · 이창영¹

국문 초록

난치성 간질환자의 수술에서 좋은 결과를 위한 중요한 인자는 간질유발부위를 정확하게 알아내는데 있다. 그러나, 수술전의 다양한 검사결과들이 어느 국소부위에 일치된 소견이 보인다면 수술계획을 비교적 쉽게 세울 수 있으나, 간질과의 시작부위가 애매한 경우에는 수술여부와 수술 위치의 결정을 위해서는 두개강내 전극을 이용한 검사가 필요하다.

두개강내에 전극을 넣는 방법은 흔히 2~8개의 뇌경막하 전극(subdural electrode)을 뇌 표면으로 넣는 방법과, 4~10개 이상의 심부 전극(depth electrode)을 뇌실질속으로 관통하여 넣는 다소 침습적인 방법이 있다. 이에 저자들은 본원에서 주로 사용하고 있는 뇌경막하 전극(subdural strip electrode)의 적응기준과 그결과를 통해, 침습검사(extratemporal recording)의 이용에 관한 지표로 삼기위해, 1993년부터 시술. 검사한 첫 50례의 경험을 분석하였다.

적용기준을 보면 간질 시작부위의 측방화가 불분명한 경우(46%)와, 술전검사의 불일치(34%), 그리고 외측두엽(extratemporal)이 의심되는 경우(20%) 등이었다. 두개강내 전극 삽입후 지속적 뇌파-비디오 검사는 평균 4.3일(2~14일) 시행하였고, 발작은 평균 5.9회 관찰. 분석하였는데, 그 결과 34례(68%)에서 국소 제거수술을 위한 충분한 소견이 보였다. 특히 측두엽간질인 경우에는, 뇌경막하 전극(subdural strip electrode)을 측두엽 기저부를 통해 내측의 부해마회(parahippocampal gyrus)에 까지 위치시켜 양측을 비교해야 한다. 전례에서 출혈이나 감염 등의 합병증은 없었다. 따라서 뇌경막하 전극(subdural strip electrode)의 시술은 안전하고 용이하며, 그 효용성에서도 난치성 간질의 해결에 많은 도움을 줄 수 있는 방법이다. (J Korean Epilep Soc 2 : 20-25, 1998)

중심 단어 : 간질수술 · 뇌경막하 전극 · 두개강내 검사 · 측두엽 간질 · 합병증.

INTRODUCTION

The use of intracranial electrodes for localizing ambiguous epileptogenic foci was popularized by Talairach and Bancaud.¹⁾ In many epilepsy centers, depth electrodes have become the standard method for precisely documenting the lateralization and lobe of an epileptogenic focus prior to ablative surgery. However, depth electrode implantation has a known and theoretical morbidity and mortality. One alternative to depth electrodes is subdural strip electrodes, which were first used by Pen-

field and Jasper and then by Marsan and Van Buren.²⁾ Unlike depth electrodes, this technique does not directly penetrate the brain parenchyma, but it has the potential to cause complications such as subdural hematoma. However, the relative risks of depth and subdural strip electrodes are not known. Therefore, the morbidity and results of various intracranial recording methods need clarification before firm statements of their relative benefits can be made. Consequently, we report our results from initial 50 consecutive and prospectively studied patients with medically intractable epilepsy who underwent implantation of subdural strip electrodes.

MATERIALS AND METHODS

1. Patient population

We have applied combined placements of mesial and lateral temporal and/or frontal subdural electrodes in 50 patients who had intractable complex partial seizures.

¹계명대학교 의과대학 신경외과학교실, ²간질센터 및 의과학연구소
Department of Neurosurgery¹, Neurology and Epilepsy Center², Keimyung University School of Medicine, Taegu, Korea

Corresponding author : Eun-Ik Son, Professor of Neurosurgery and Epilepsy Center Keimyung University School of Medicine 194 Dongsandong, Taegu, 700-712 Korea
TEL : (053) 250-7306 · FAX : (053) 250-7356
E-mail : drson@dsmc.or.kr

they comprise 31 males and 19 females.

The indications for placement of subdural strip electrodes to confirm the existence and site of epileptogenic foci by recording the site of seizure onset directly from the brain surface assume that the patient is suspected of having a potentially resectable epileptogenic focus, but the exact location of this focus is unknown.^{3,6}

All patients were monitored initially with long-term scalp EEG/video recordings, which usually included sphenoidal electrodes. Therapeutic decisions could be made based on these data when considered with appropriate neuroimaging and complete neuropsychological testing. For the patients who comprise these data, the scalp EEG monitoring was not considered precise enough to resolve their diagnosis or to decide if they were candidates for epilepsy surgery. The majority of these cases were problematic because of the following ambiguities in scalp recordings (Table 1).

1) The laterality of ictal onset was not clearly identified because onset was simultaneous (frontal and/or temporal) bilaterally (1A) or the clinical seizure apparently preceded the EEG onset (1B). For example, a patient has been found by long-term extracranial EEG-video monitoring to have complex partial seizures, but the EEG ictal onset appear to be non-lateralized, or, if lateralized, not clearly focal. To lateralize and localize the focus, subdural strips are implanted bilaterally at sites likely to be the site of the focus by long-term ictal EEG/Video monitoring.

2) Confirmatory recordings would often arise in cases when confounding discrepancies exist among localizing data, semiology (2A), neuroimaging (CT, MRI, SPECT, etc.) and neuropsychological studies (2B), accumulated during the presurgical evaluation. As a typical example, a patient may have a potentially epileptogenic structural lesion in one region of the cortex, but the extracranial EEG monitoring might suggest seizures arising elsewhere.

Table 1. Indications of intracranial recording with subdural strip electrodes and categorization of 50 consecutive cases with difficult epileptic problems

1. Unclear lateralization of ictal onset	23 (46%)
1A : simultaneous bilaterally	20
1B : clinical seizure preceded the EEG onset	3
2. Confounding discrepancies	17 (34%)
2A : semiology	9
2B : neuroimaging, neuropsychometry	8
3. Ambiguous extratemporal ictal onset	10 (20%)

In such an individual, strip electrodes were implanted so that ictal monitoring can confirm whether or not the epileptogenic focus is truly associated with the lesion.

3) Ictal onset could not be distinguished clearly between the temporal and frontal lobe from one hemisphere (extratemporal : 3). A common problem was observed from a patient in whom the epileptogenic focus was strongly suspected to be within one cerebral hemisphere but the anatomical or clinical data do not localize it to either the frontal or temporal lobe.

2. Operative procedure

Subdural strip electrodes are surgically implanted under general anesthesia. A small skin incision (no larger than is necessary for making a cranial burr hole) is made at the desired location and a standard sized burr hole is drilled. Dural bleeding is controlled with a bipolar coagulator and then the dura is opened with a T-shaped incision. Although some surgeons use mannitol and/or hyperventilation to shrink the brain we have found this nearly unnecessary. During the surgical procedure the electrodes are kept covered until each is needed for insertion. The electrode is then rinsed in irrigation solution before insertion. An angled dissector can help guide the strip electrode in the proper trajectory as the electrode is slid into position. The dura is not closed. The electrode wires are tunneled with a large-bore needle to exit the skin several centimeters from the burr hole incision. The electrodes manufactured by Ad-Tech Corp. (Racine WI.) have all wires incorporated into a monostrand cable. This simplifies passing the wires transcutaneously and decreases CSF leakage postoperatively. We place a cable-retaining suture in the scalp because this has not increased the risk of breaking the electrode cable. The idea of the retaining suture is to allow a degree of resistance to pulling out the electrode during a seizure. Since we are interested in the site of seizure onset rather than the late generalized activity, we would prefer that the cable become detached instead of broken or that the electrode became dislodged or displaced. The wounds are closed in layers using vicryl sutures in the deep fascia and staples for the skin. The patient is taken to the recovery room where AP and lateral skull X-rays are obtained to confirm the electrode positions. This can also be done with a CT scan. With the CT scan the basal temporal electrodes are often difficult to visualize unless special

thin cuts with coronal section are taken through the middle fossa region (Fig. 1). Although MRI compatible strip electrodes are available, they are not easily visualized on MRI.

3. Electrode positioning

For most routine exploratory implants we prefer a standard montage that uses four burr holes. Burr holes are opened bilaterally over the temporal lobes and frontal lobes (Fig. 2). The temporal burr holes are located just anterior to the ear and superior to zygoma. Through this hole a four-contact six-cm strip is directed medially so that the most distal electrode contact records from the parahippocampal gyrus. A second four-contact six-cm strip is inserted through the same burr hole and directed posteriorly and laterally to overlay to middle temporal gyrus. If an occipital focus is suspected, an 8-contact 9-cm (or even 16-cm) strip electrode can be introduced posteriorly through the temporal burr hole to sample la-

teral occipital cortex in place of the 6 cm lateral temporal strip. The reason for placing medial and lateral temporal strips is to determine if seizure onset is from medial or lateral temporal cortex or from both areas simultaneously (thus termed a regional temporal onset). Strip electrodes are routinely inserted bilaterally. These informations are important for planning an appropriate surgery as well as predicting the seizure outcome from surgery.

It is also controversial that when suspecting a frontal lobe epileptogenic focus, mesial temporal strip electrodes should be included.^{7,9}

RESULTS

A total of 50 consecutive patients underwent strip electrode implantation and were followed-up for at least 30 days after strip removal. Thirty one patients were male and nineteen female. The age range was 12–41 years. The follow-up ranged from 15 to 40 months. The duration of electrode implantation ranged from 2 to 13 days for at least three spontaneous seizures, with the average being 4.3 days (Table 2).

Of the 50 consecutive patients studied, localization was sufficiently adequate in 34 allowing a decisions for focal resection. Four patients had inconclusive monitoring, no definitive diagnostic or therapeutic decision could be derived from their recordings. The remaining 12 patients were divided into two groups : a nonfocal surgical group and a nonfocal nonsurgical group. The first group consisted of 8 patients. Of the 8, seven patients accepted and one declined surgery. The other 4 patients, of the second group following monitoring, were judged not to be candidates for either type of surgery (Table 3).

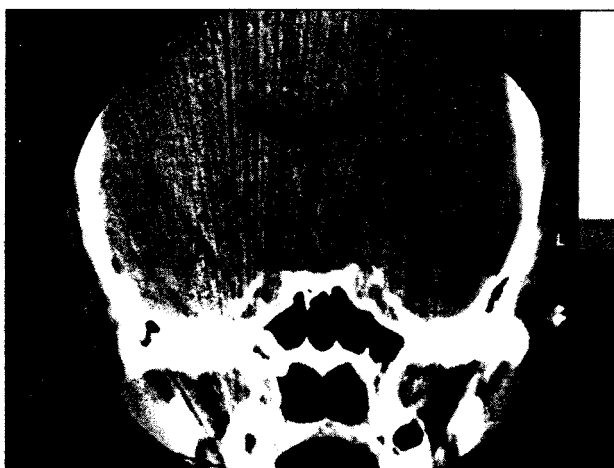


Fig. 1. Brain CT (coronal) shows deeply implanted bitemporal subdural strip electrodes into the medial temporal lobe (Arrows indicate the tip of 4 contact electrodes near the posterior clinoid process).

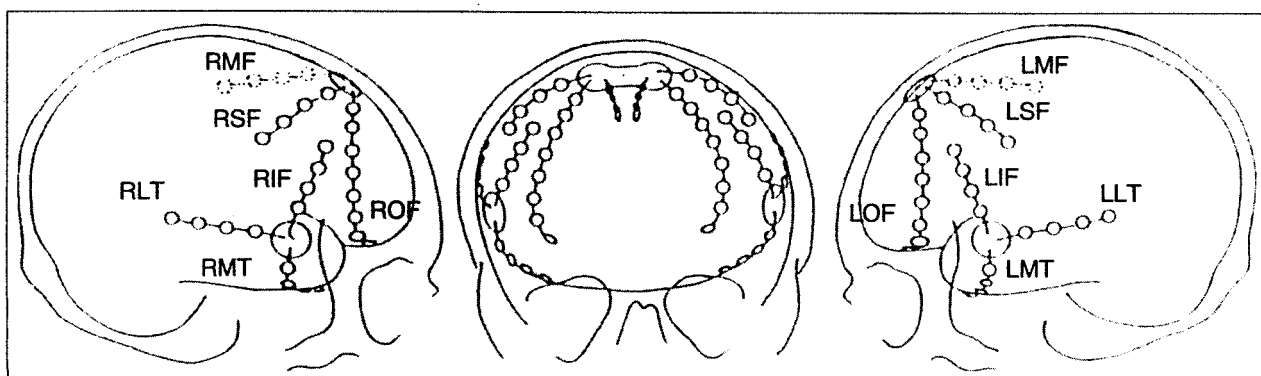


Fig. 2. Sketches of radiological studies with location of subdural strip electrodes and respective nomenclature. R ; right, L ; left, M ; medial, L ; lateral, F ; frontal, T ; temporal, OF ; orbito-frontal.

Table 2. Characteristics of 50 patients with subdural strip electrodes

Age at operation	Mean : 25.4 years (range : 12-41)
Sex	M/F : 31/19
Duration of implantation	Mean : 4.3 days (range : 2-14)
Seizures during monitor	Mean : 5.9 (range : 2-over 10)
Surgery cases	39 (78%)/50 strip patients
Side of Surgery	Right/left : 21/18
Location of Surgery*	TLE/ETE : 29/10 (F6, P3, O1)*

*TLE : temporal lobe epilepsy, ETE : extratemporal epilepsy
F : frontal, P : parietal, O : occipital

Table 3. Results of chronic subdural strip electrode recordings in 50 consecutive patients

Sufficient localization for focal resection	34 (68%)
Inconclusive monitoring	4 (8%)
Non-focal group	12 (24%)
A nonfocal surgical group	8*
A nonfocal nonsurgical group	4

*seven patients accepted and one declined surgery

DISCUSSION

To avoid confusion between terms, we define strip electrodes as intracranial devices for recording the electrode contacts. The number of contacts per electrode can vary, depending upon what is required by the individual case. Common strip electrode lengths are five to nine cm with four to eight electrode contacts in each strip, but can be up to sixteen cm in length. Strip electrodes are distinguished from parallel rows of multiple electrode contacts that make up a grid electrode. Both grid and strip electrodes are implanted intracranially over the cortical surface. These are in contrast to depth electrodes that are inserted through the brain parenchyma to reach deep recording sites. Strip electrodes are made from biologically inert, flexible materials (such as Silastic and Teflon) and commonly have stainless steel electrode contacts. Recently, manufacturers have made available strips with platinum disk electrodes as well as silver electrodes that are MRI compatible.

Subdural strip electrodes have both advantages and disadvantages in comparison to depth electrodes. The advantages are : 1) they are easier to implant than depth electrodes because they do not require the equipment or expertise needed for stereotaxic surgery.⁶¹⁰ 2) They require less time to implant and thus the total operating room and anesthesia costs are less than depth electrodes.

3) They can cover larger expanses of cortex than depth electrodes. 4) They appear to have a lesser risk of mortality and morbidity than depth electrodes.³⁸⁰¹¹⁾

The disadvantage to subdural strip electrodes is their inability to record from the hippocampus and amygdala. Therefore, some researchers have claimed they are inferior to depth electrodes for evaluating patients for temporal lobe surgery. However, one study used strip electrodes placed over the temporal lobes through a vertex burr hole, and therefore, they could not be sure the electrodes were recording from medial temporal regions. Reports from other centers have shown that subdural strip electrodes can provide sufficient data to make accurate surgical decisions. In two studies,¹²¹⁵⁾ the EEG was recorded simultaneously from both depth and subdural strip electrodes and the subdural electrodes localized the seizure onsets as well as depth electrodes did.

There is no possible way to compare the relative cost/benefit ratios of depth and strip electrodes. This is because of several factors : 1) the relative complication rates between the two techniques are not known, 2) different surgical centers use different electrode shapes and sizes from different manufacturers, 3) the techniques for implantation have not been standardized, 4) the length of time electrodes are left implanted are not standardized because the total number of seizures that need to be recorded to gather sufficient information is not set. Thus, there are numerous variables that can not be accurately accounted for, so such comparisons are impossible to make with certainty. The same arguments apply to a cost/benefit comparisons between surgical series from centers that select patients solely on interictal scalp when compared to centers that heavily utilize ictal invasive data for patient selection. The argument can not be answered due to short of a well designed prospective study that addresses this specific issue.

The need for bilateral strip electrodes is self-evident in exploratory recordings of patients who have nonlateralized seizure onsets in extracranial EEG studies. In other cases, however, the reason for using bilateral electrodes may not be as obvious. In all patients, bilateral strip electrodes subserve comparative EEG observations which often are crucial for identifying the side from which seizure is arising. Importantly, bilateral electrode placement appropriately precludes any chance that electrodes might have been inadvertently placed only on the side to which

seizures had spread rather than on the side of onset. Regardless of what might be anticipated, seizures of some patients arise unilaterally on an unsuspected side. Lastly, in temporal lobe epilepsy, bilateral strip electrode placements furnish important data, such as the interhemispheric propagation time. Engel et al. reported that poor postsurgical seizure relief was associated with seizure propagation to the contralateral side in less than five seconds, whereas good outcomes were associated with propagation time of greater than fifty seconds. Although the data of Engel et al. were derived from studies with depth electrodes (and are most applicable for patients suspected of having mesial temporal lobe foci), we have found the same to be valid for seizures of temporal lobe origin recorded by subdural strip electrodes. Therefore, because bilateral electrodes can provide crucial prognostic information besides focus localization, virtually all cases require them.

The morbidity of strip electrodes is quite small. The primary concern is infection. However, the complications that have been reported are few. Wyler et al.¹³ reported one minor brain abscess and one cortical contusion in twenty-eight patients early in the development of the technique. Rosenbaum et al.⁹ had no morbidity for fifty patients implanted an average of seven days. Wyler et al.⁹ reported initial results from an ongoing prospective study

to evaluate the morbidity of subdural strip electrodes in general and the use of prophylactic antibiotics in particular. They divided 350 consecutive patients into two groups, one receiving antibiotics throughout the time the electrodes were in place, the other group receiving antibiotics in one bolus the morning of electrode insertion. They found an overall infection rate of 0.85% with no difference between the two groups. They are presently evaluating another group of patients who are being given no antibiotics. Other reported complications have been accidental extraction of electrodes, cortical contusion, subdural empyema, and superficial wound infection. Many of these complications are minor, leaving no long-term problem. In our fifty consecutive series, there is absolutely no complication except one small cortical contusion.

In conclusion, subdural strip electrodes provide a safe reliable method for long-term invasive ictal monitoring in the presurgical evaluation of patients considered for epilepsy surgery.^{6,14} Although they do not allow for recording from amygdala or hippocampus directly, they provide safe and sufficient information to localize and lateralize an epileptogenic focus so that one can proceed with a focal resection when indicated.^{13,15}

- 논문접수일 : 1998년 4월 3일
- 심사통과일 : 1998년 7월 10일

REFERENCES

- 1) Lieb JP, Engel J, Jr, Babb TL. Interhemispheric propagation time of human hippocampal seizures. I. Relationship to surgical outcome. *Epilepsia* 1986;27:286-93.
- 2) Luders H, Hahn JF, Lesser RP, et al. Basal temporal subdural electrodes in the evaluation of patients with intractable epilepsy. *Epilepsia* 1989;30:131-42.
- 3) Rosenbaum TJ, Laxer KD, Vessely M, et al. Subdural electrodes for seizure focus localization. *Neurosurgery* 1986;19:73-81.
- 4) Spencer SS. Depth versus subdural electrode studies for unlocalized epilepsy. *J Epilepsy* 1989;2:123-7.
- 5) Spencer SS, Williamson PD, Spencer DD, et al. Human hippocampal seizure spread studied by depth and subdural recording: The hippocampal commissure. *Epilepsia* 1987;28:479-89.
- 6) Van Veelen CWM, Chr. Debets RM, Van Huffelen AC, et al. Combined use of subdural and intracerebral electrodes in preoperative evaluation of epilepsy. *Neurosurgery* 1990;26:93-101.
- 7) Wyler AR, Ojemann GA, Lettich E, et al. Subdural strip electrodes for localizing epileptogenic foci. *J Neurosurg* 1984;60:1195-200.
- 8) Wyler AR, Walker G, Richey ET, et al. Chronic subdural strip electrode recordings for difficult epileptic problems. *J Epilepsy* 1988;1:71-8.
- 9) Wyler AR, Walker G, Somes G. The morbidity of long-term seizure monitoring using subdural strip electrodes. *J Neurosurg* 1991;74:734-7.
- 10) Williamson PD, Spencer DD, Spencer SS, et al. Complex partial seizures of frontal lobe origin. *Ann Neurol* 1985;18:497-504.
- 11) Blom S, Flink R, Hetta J, et al. Interictal and ictal activity recorded with subdural electrodes during preoperative evaluation for surgical treatment of epilepsy. *J Epilepsy* 1989;2:9-20.
- 12) Privitera MD, Quinlan JG, Yeh H. Interictal spike detection comparing subdural and depth electrodes during electrocorticography. *EEG Clin Neurophysiol* 1990;76:379-87.
- 13) Spencer SS, Spencer DD, Williamson PD, et al. Combined depth and subdural electrode investigation in uncontrolled epilepsy. *Neurology* 1990;40:74-9.
- 14) Devinsky O, Sato S, Kufta CV, et al. Electroencephalographic studies of simple partial seizures with subdural electrode recordings. *Neurology* 1989;39:527-33.
- 15) Smith JR, Flanigin HF, King DW, et al. Analysis of a four-year experience with depth electrodes and a two-year experience with subdural electrodes in the evaluation of ablative seizure surgery candidates. *Appl Neurophysiol* 1987;50:380-5.

Chronic Subdural Strip Electrode Recordings as Preoperative Evaluation for Epilepsy Surgery

**Eun-Ik Son, M.D., Il Man Kim, M.D., Sang Do Yi, M.D.,
Ji Eun Kim, M.D. and Chang Young Lee, M.D.**

ABSTRACT

One of the important factors in providing good results from epilepsy surgery is the accuracy of identifying the epileptogenic focus. We report a retrospective series of 50 consecutive patients who underwent chronic intracranial recordings with subdural strip electrodes. All patients had previously undergone chronic EEG/Video monitoring with scalp and sphenoidal electrodes.

The mesial temporal subdural electrodes were easily introduced to the inner uppermost part of the parahippocampal gyrus and excellent recordings of interictal and ictal events were obtained. Postoperative CT scans and simple craniograms demonstrated correct positioning of the electrodes. All patients were monitored for 2 to 14 days (mean : 4.3 days) of implantation to obtain enough seizures (mean : 5.9 seizures). The recordings enabled sufficiently accurate localization for focal resection in 34 (68%) of 50 cases with only one minor complication. Most electrodes were localized over the lateral and mesiobasal cortex of temporal lobe. However, additional strip electrodes were covered on the frontal, parietal and occipital lobe cortex in ten cases to prevent sampling error. This procedure is a relatively safe and effective method for resolving difficult diagnostic issues and a valuable alternative to placing intracerebral depth electrodes.

KEY WORDS : Epilepsy surgery · Subdural strip electrode · Intracranial recording · Temporal lobe epilepsy · Complication.